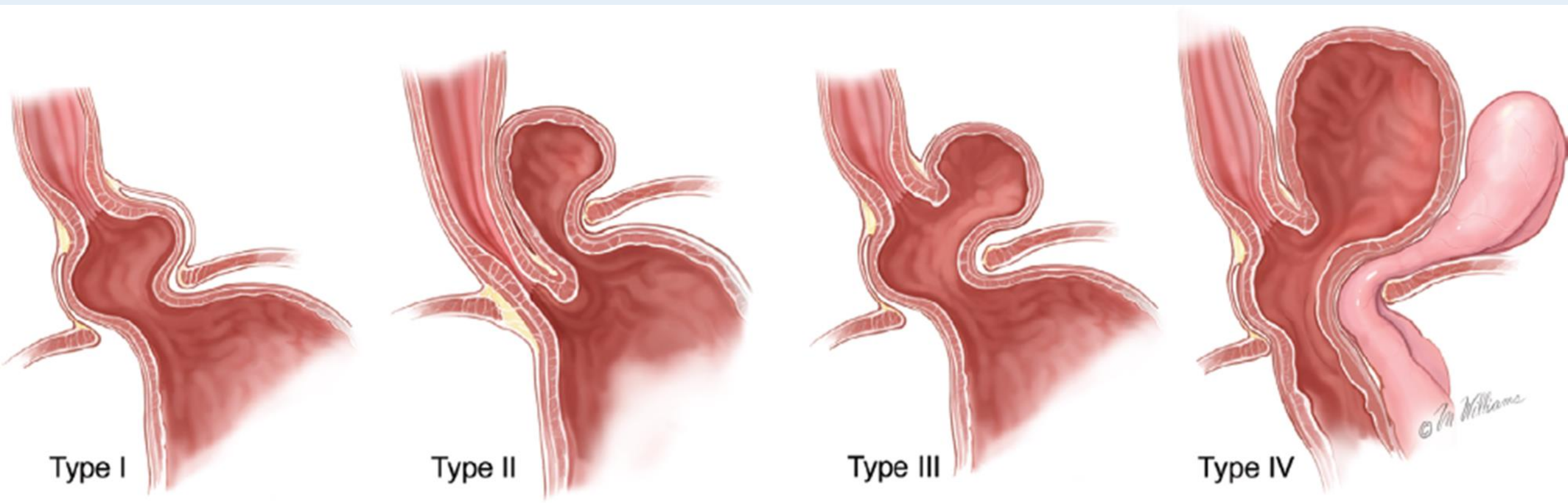


Abdominal Laparoscopic Surgeries

Laparoscopic Nissen Fundoplication
Sleeve Gastrectomy
Roux-en-Y Gastric Bypass
Laparoscopic Cholecystectomy
Laparoscopic Inguinal Hernia Repair

Laparoscopic Nissen Fundoplication in Hiatal Hernia

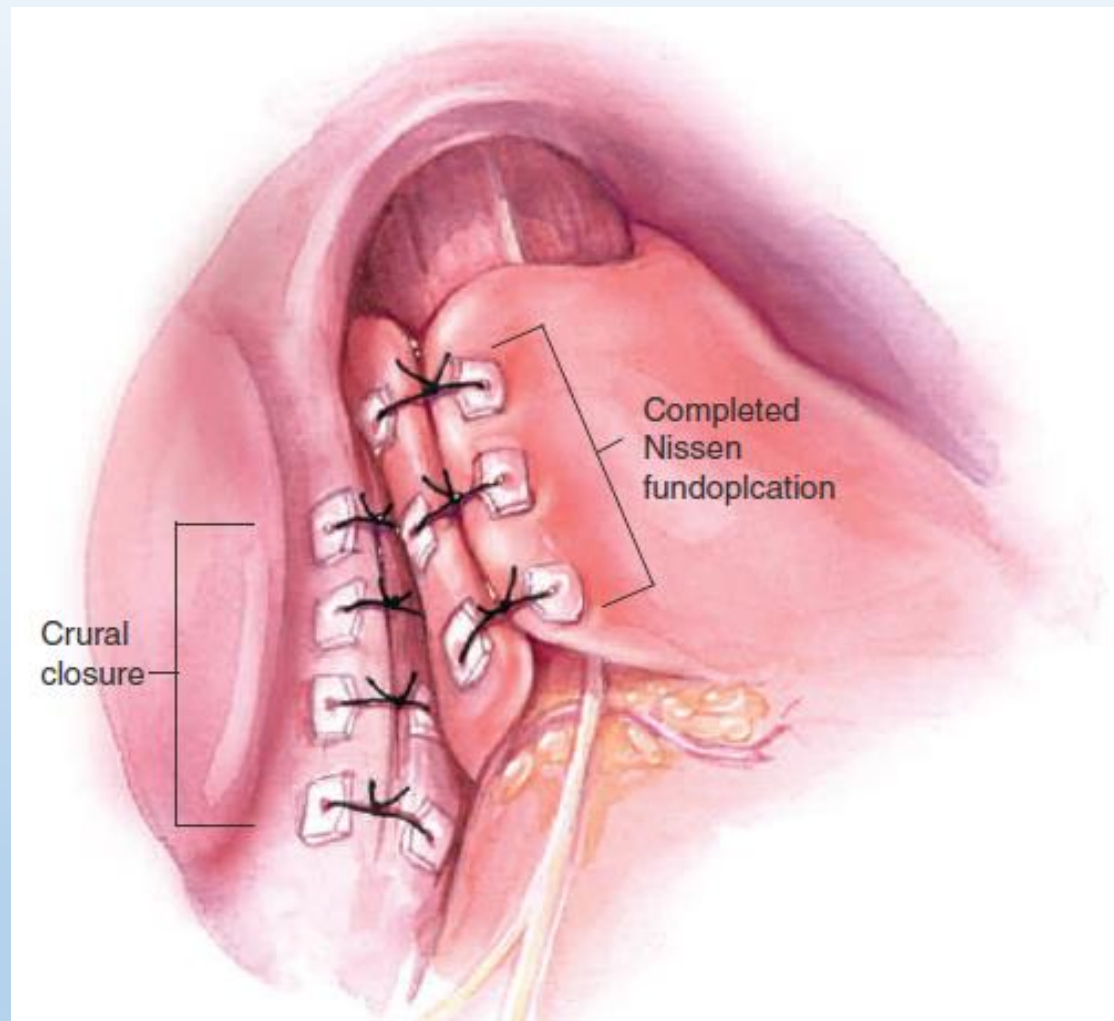
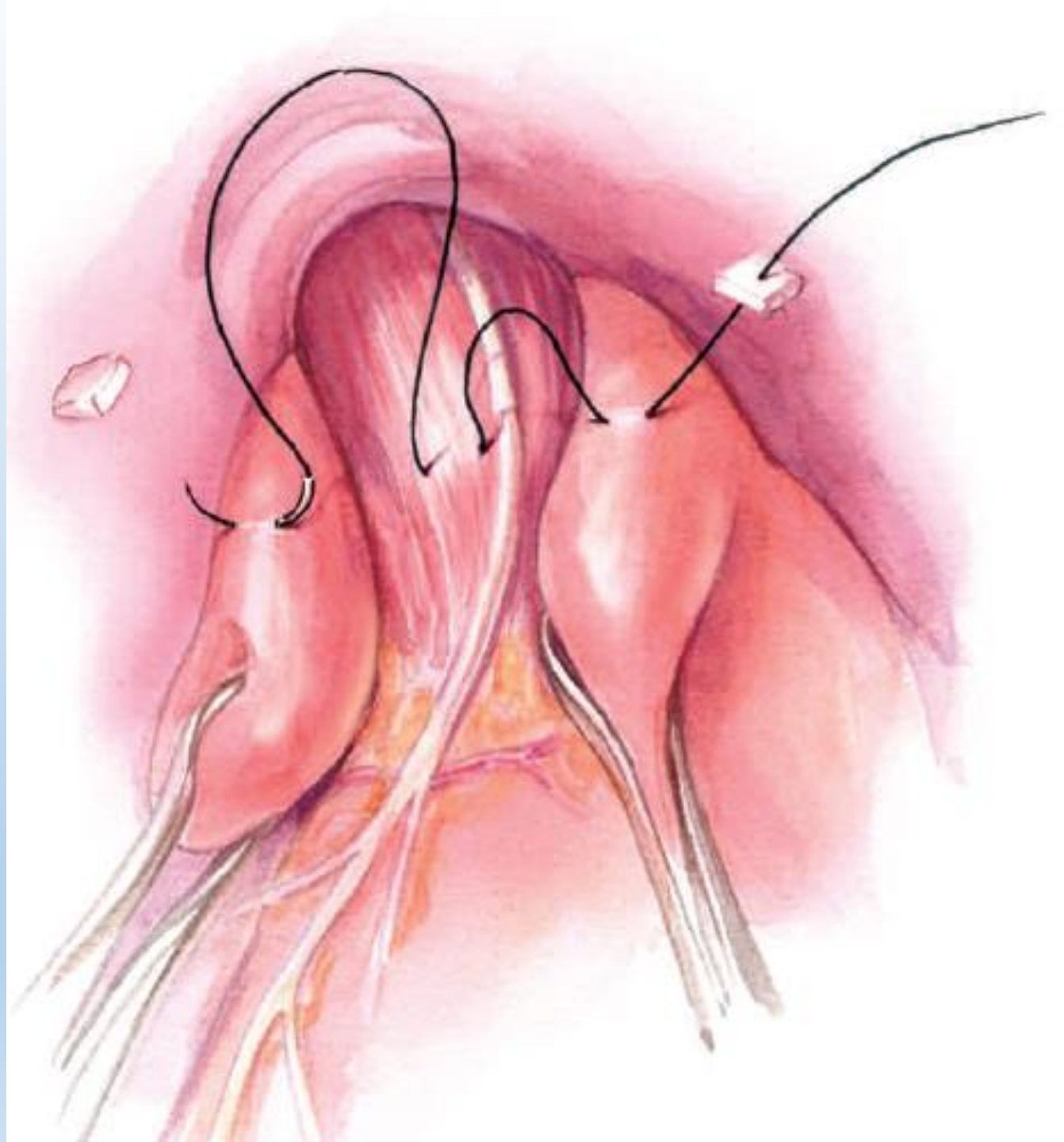

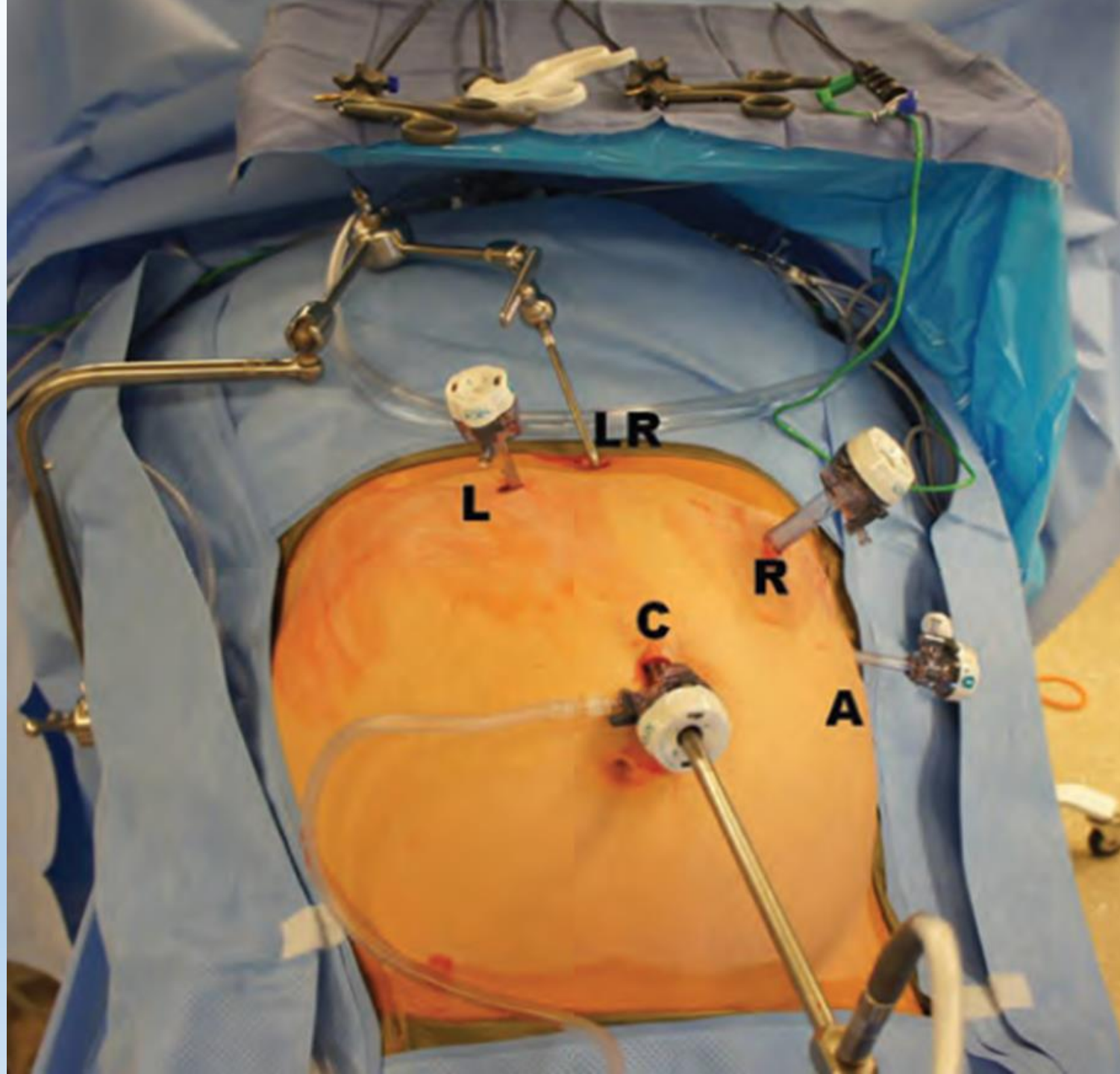
Type I

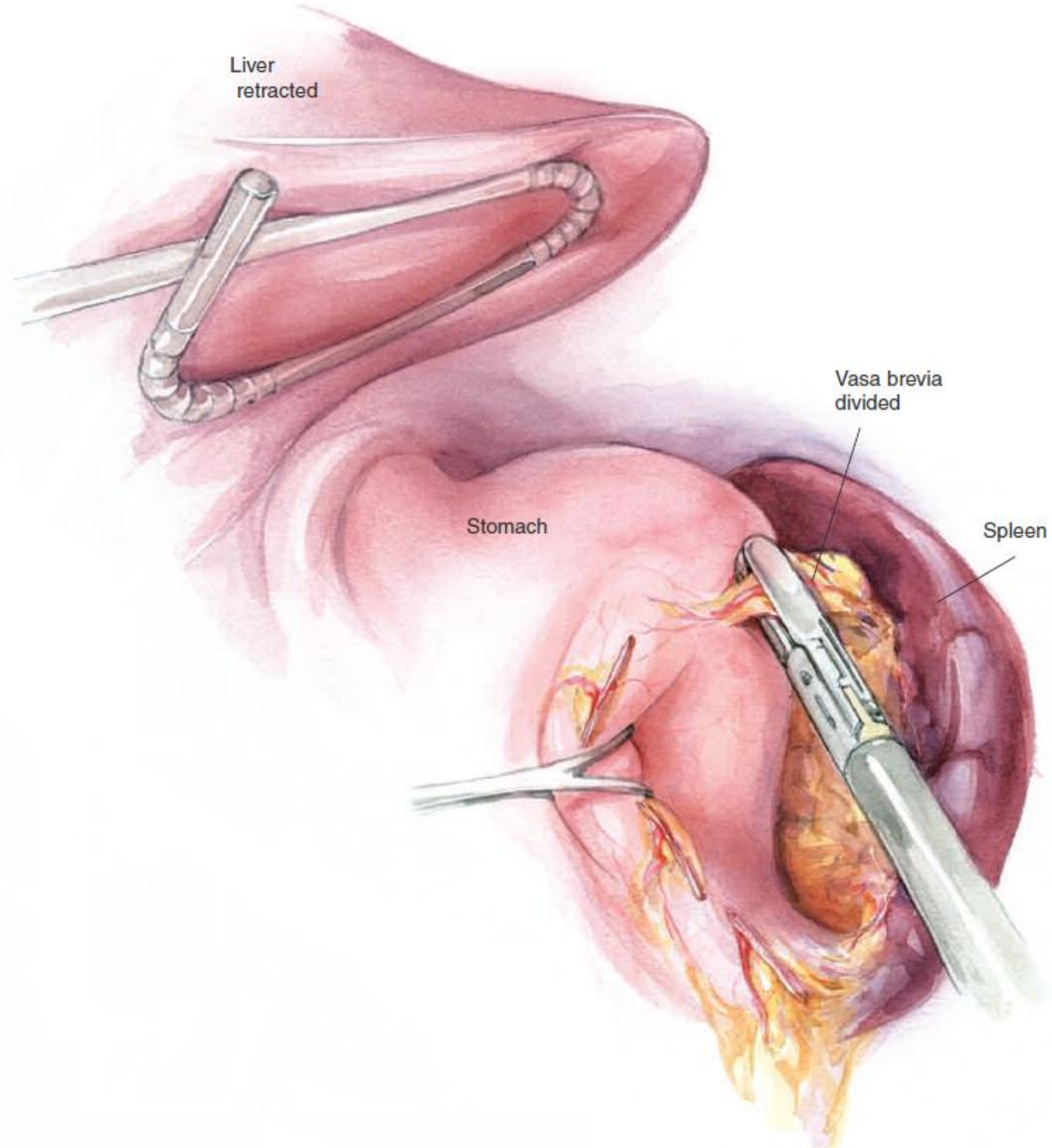
Type II

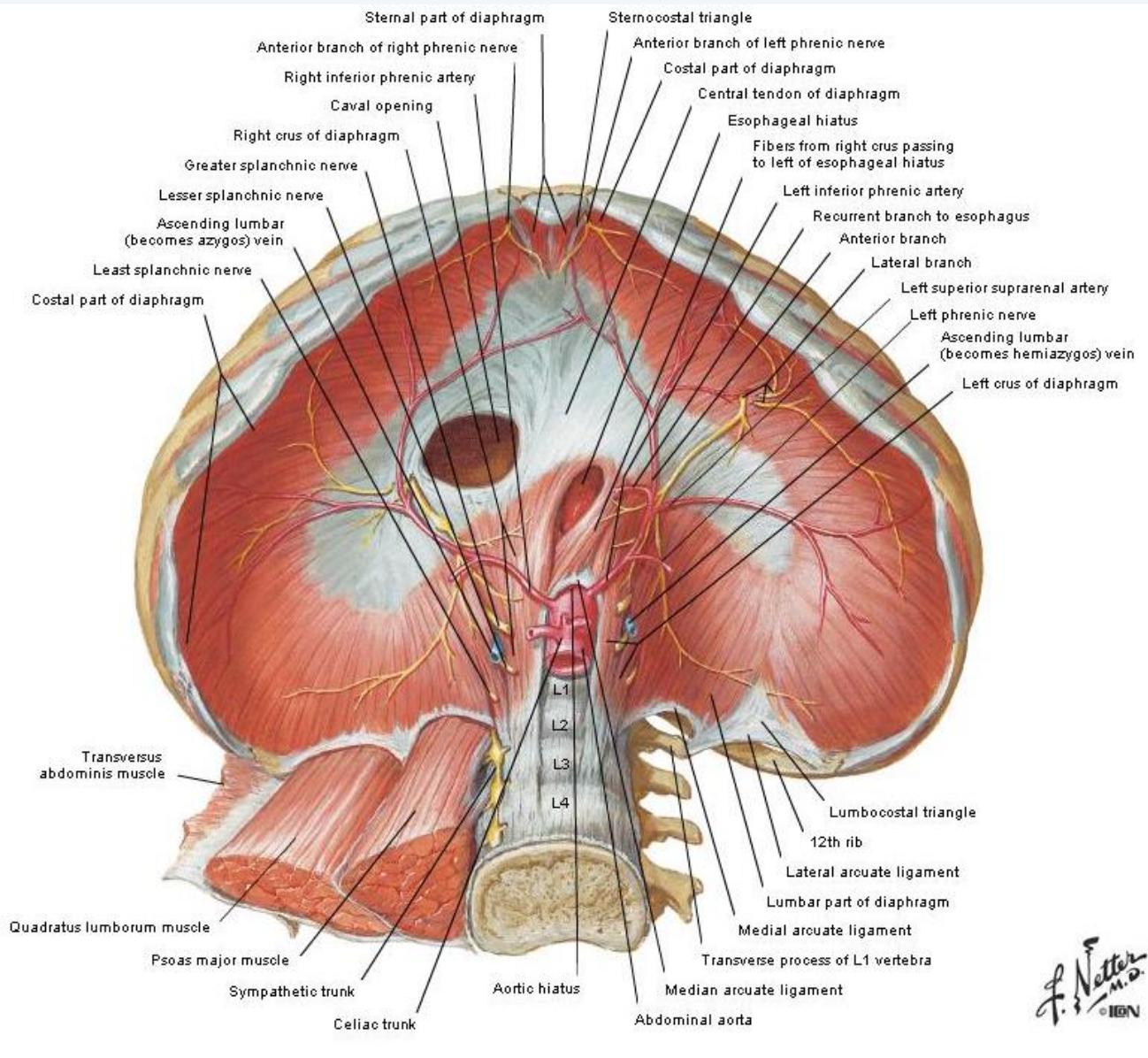
Type III

Type IV

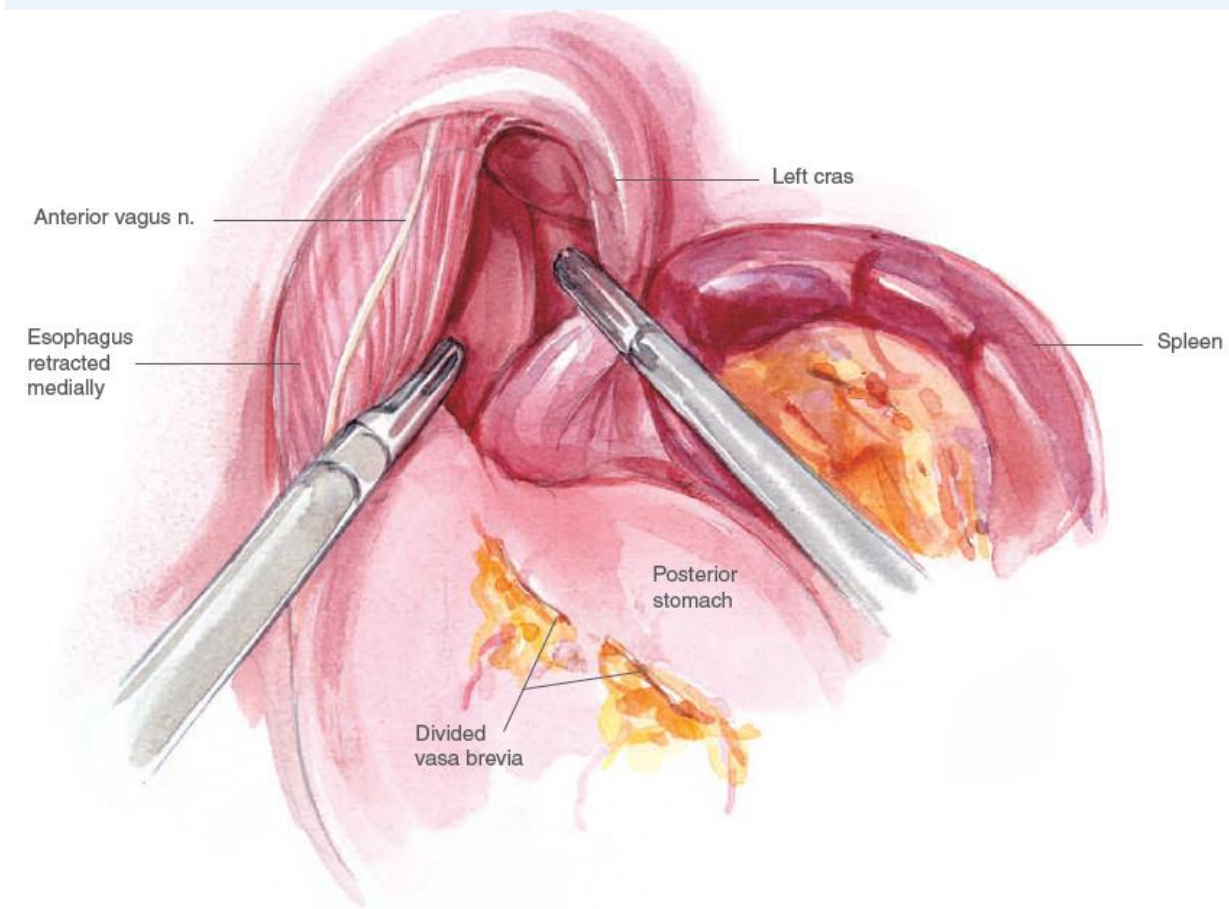


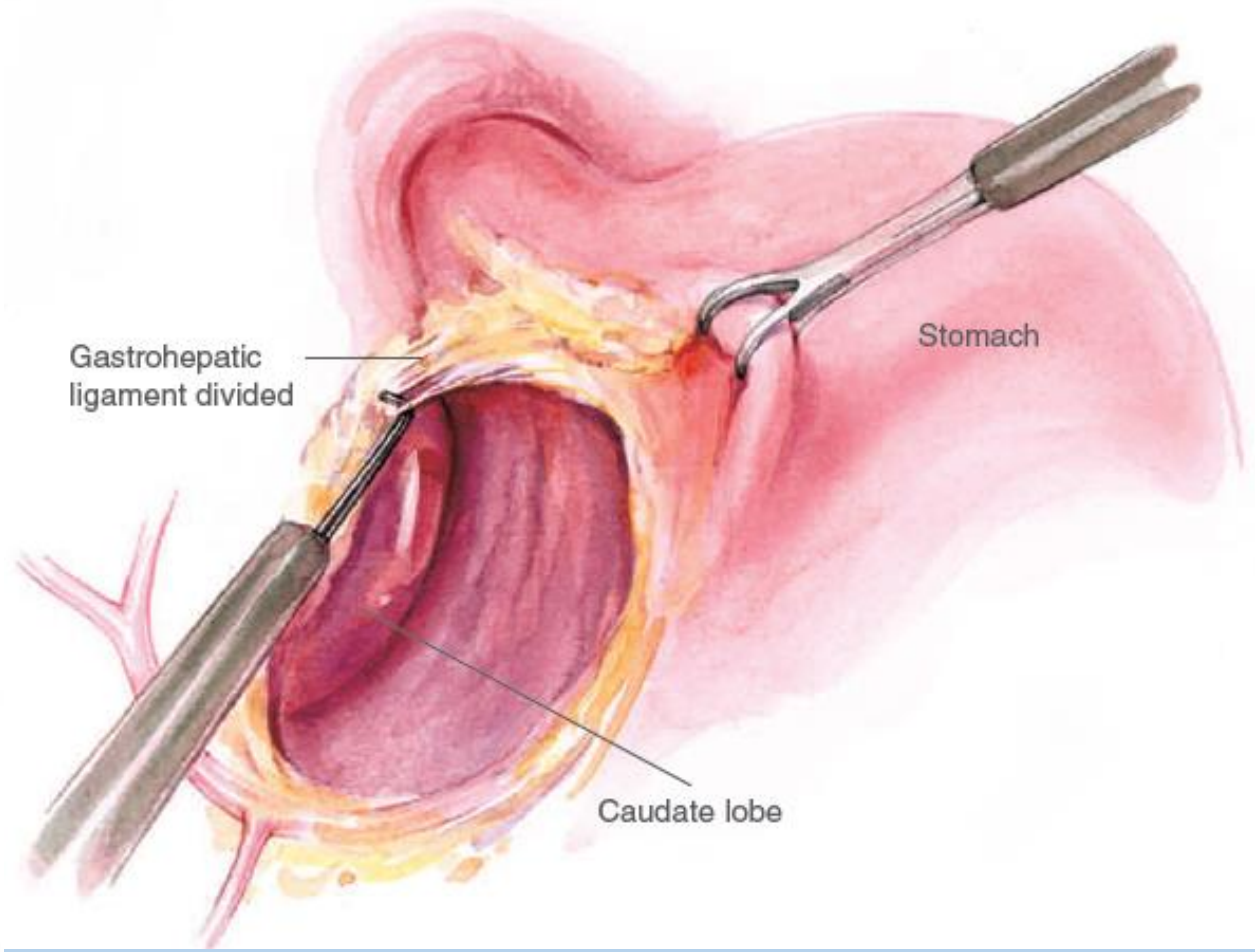
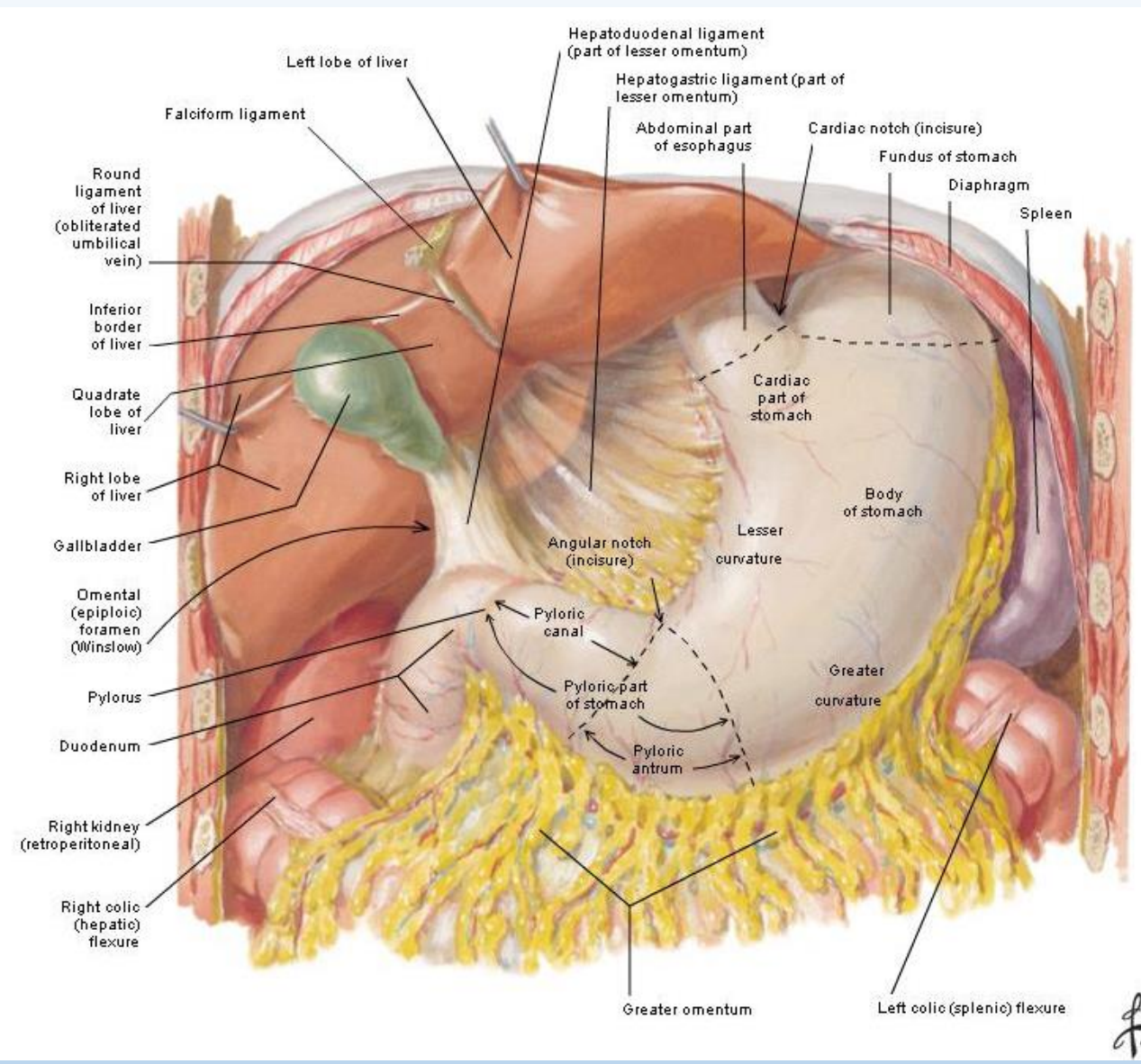


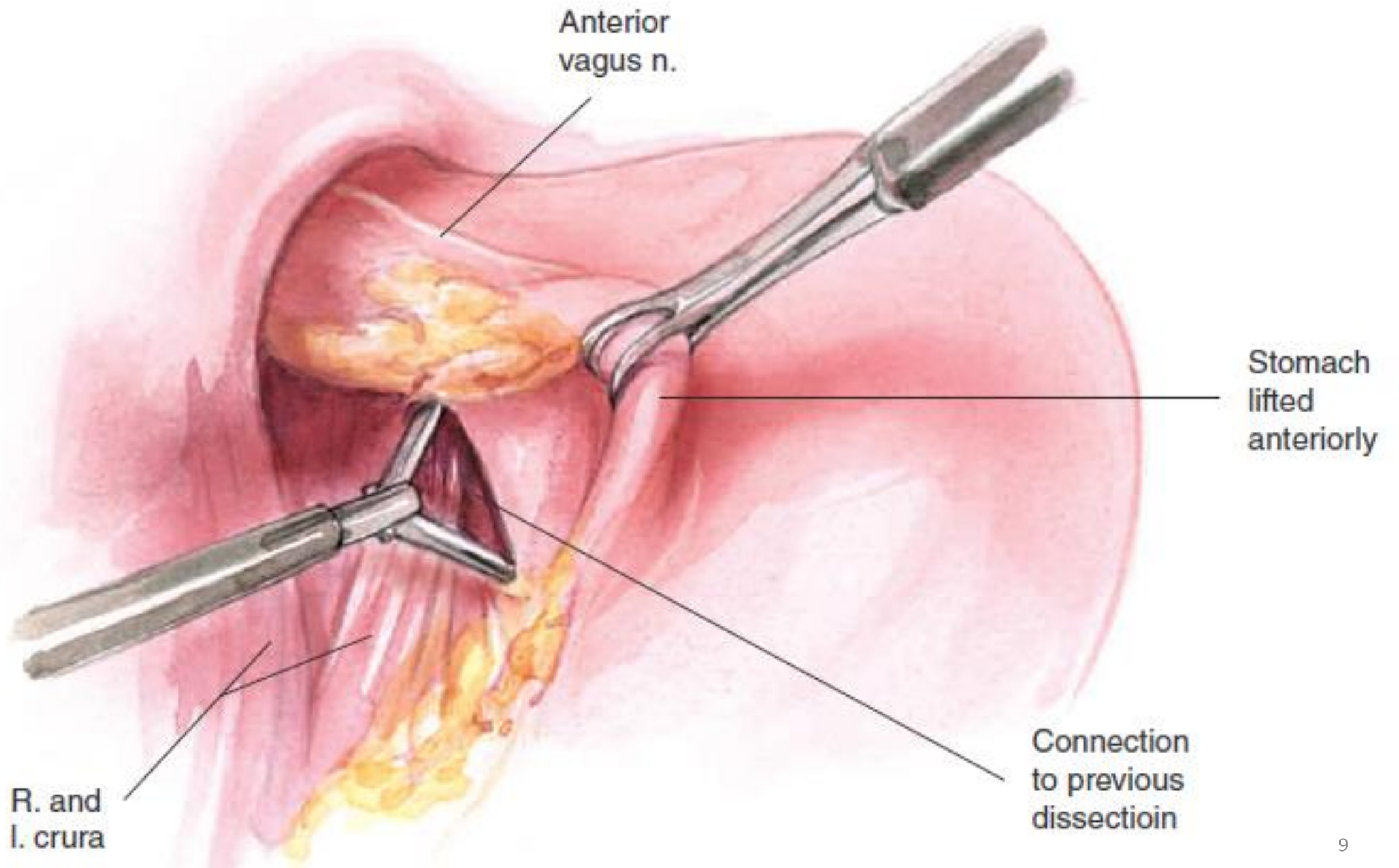




F. Netter M.D.





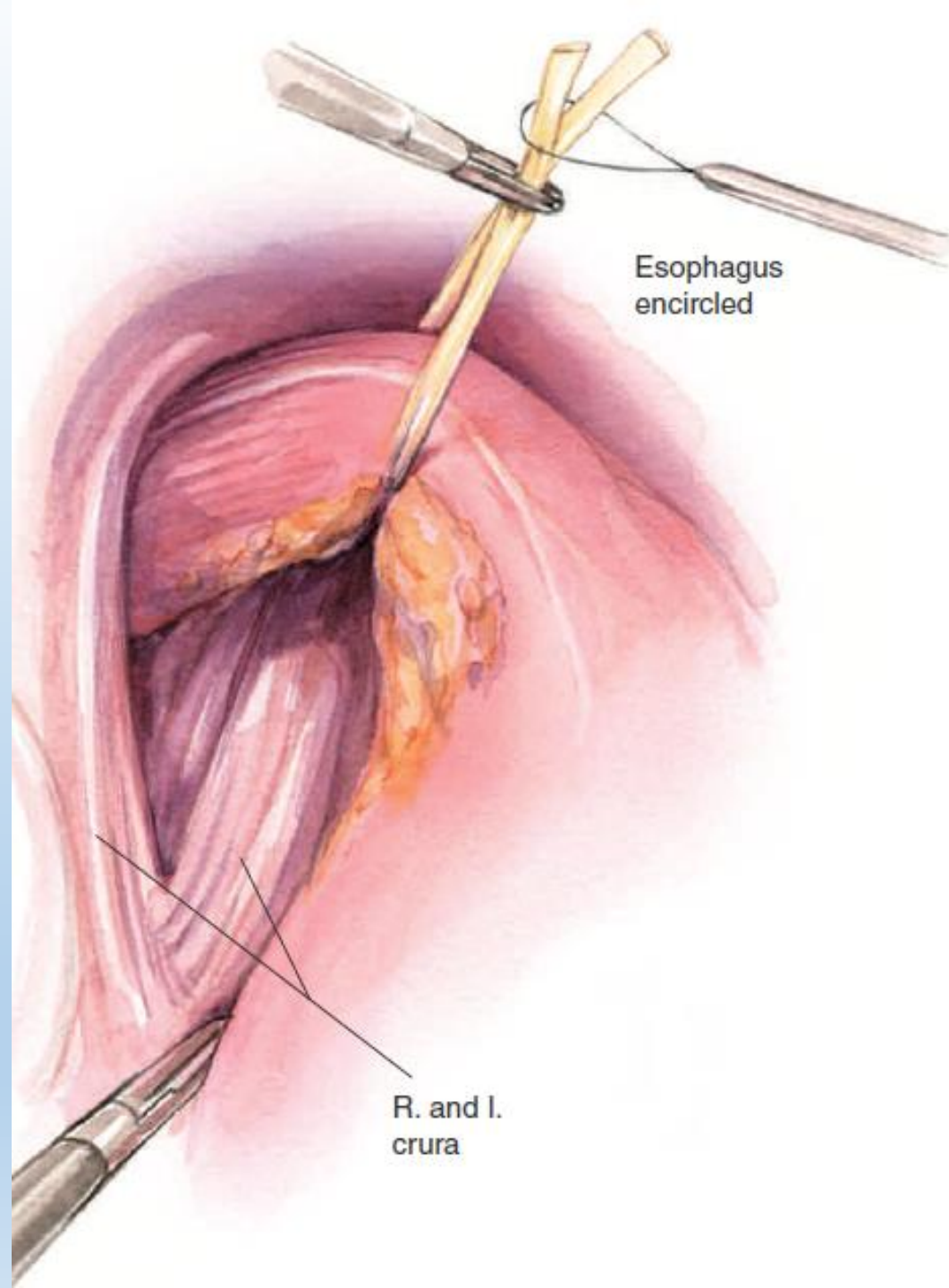


Anterior
vagus n.

Stomach
lifted
anteriorly

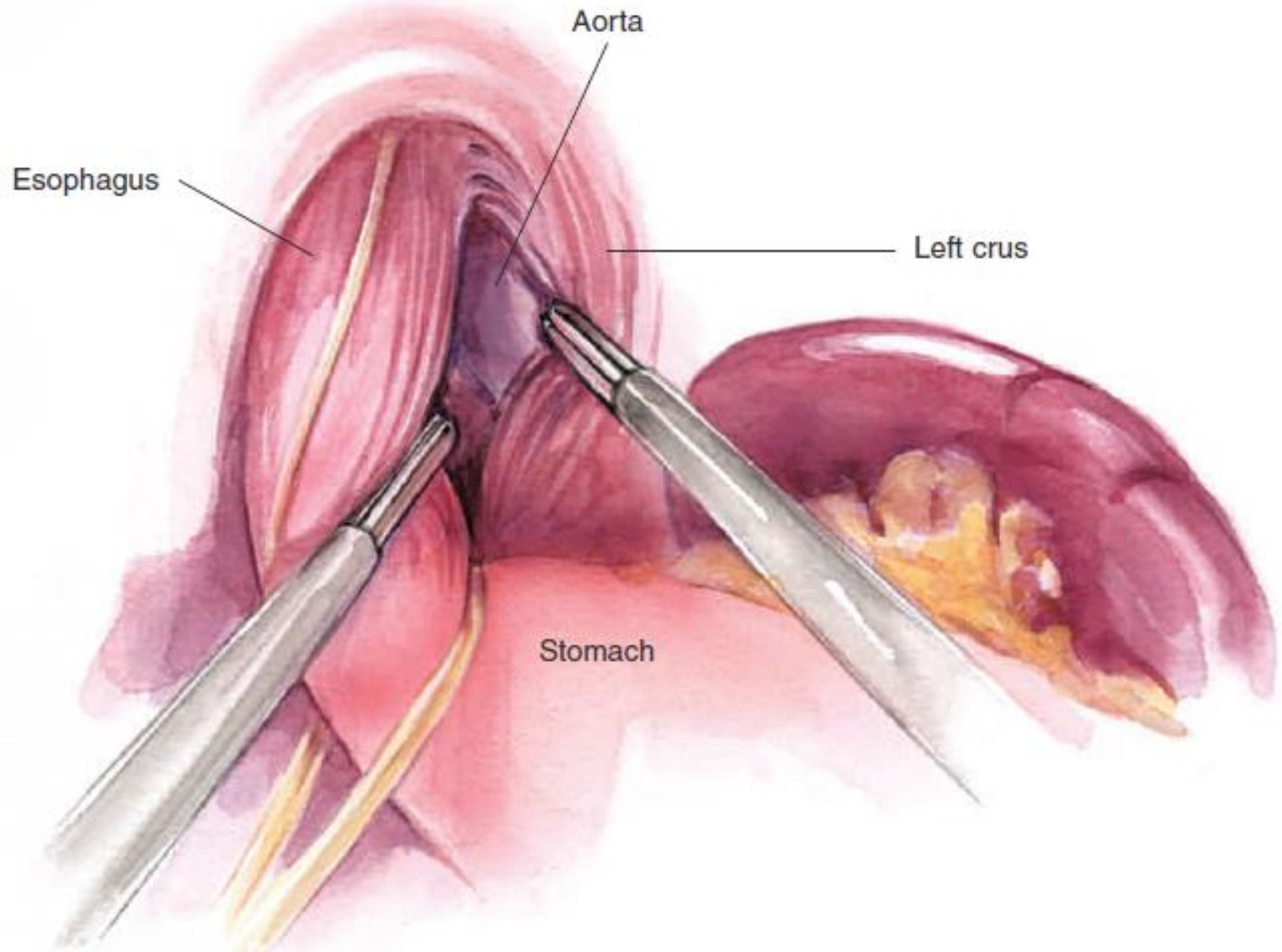
Connection
to previous
dissection

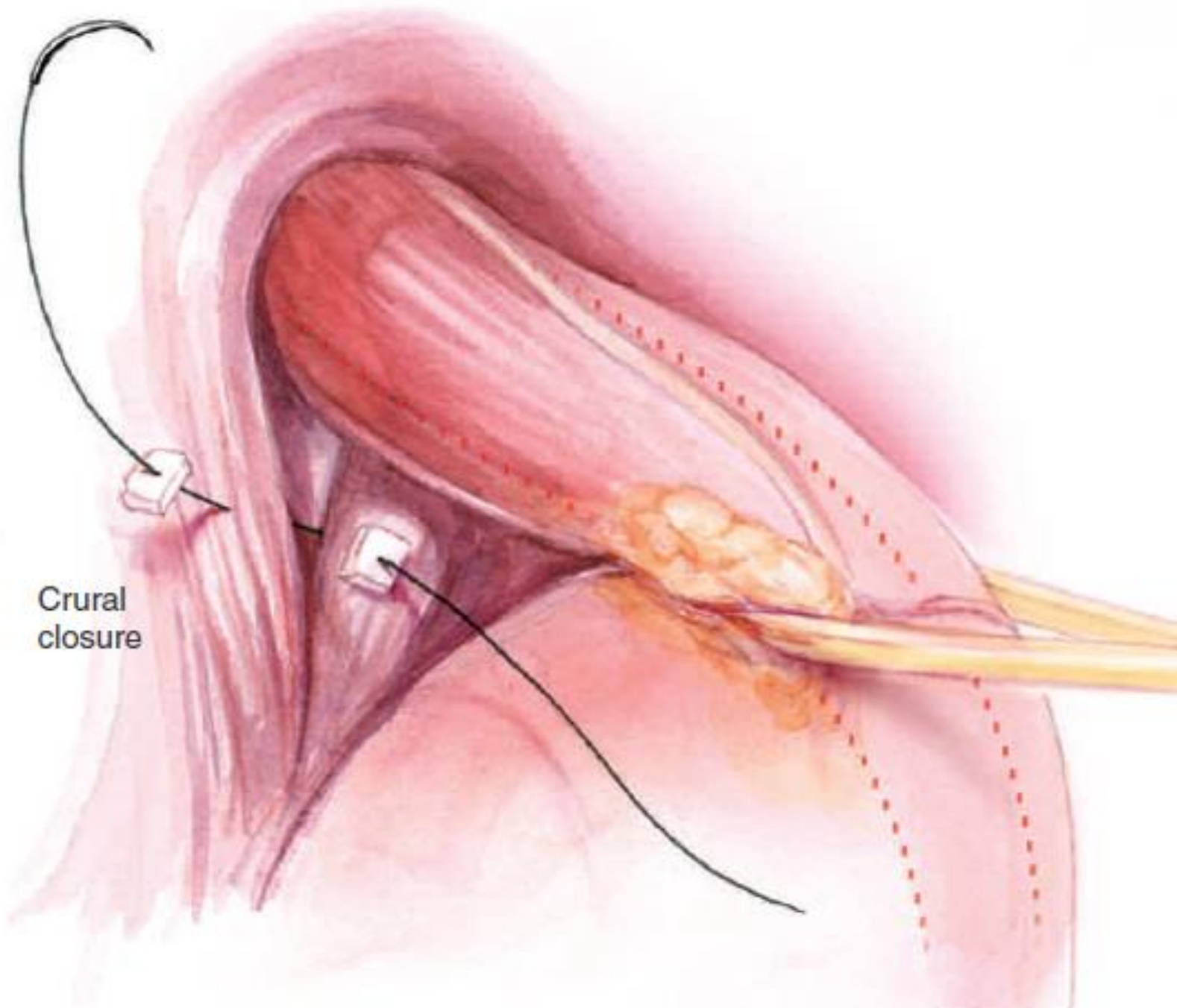
R. and
l. crura



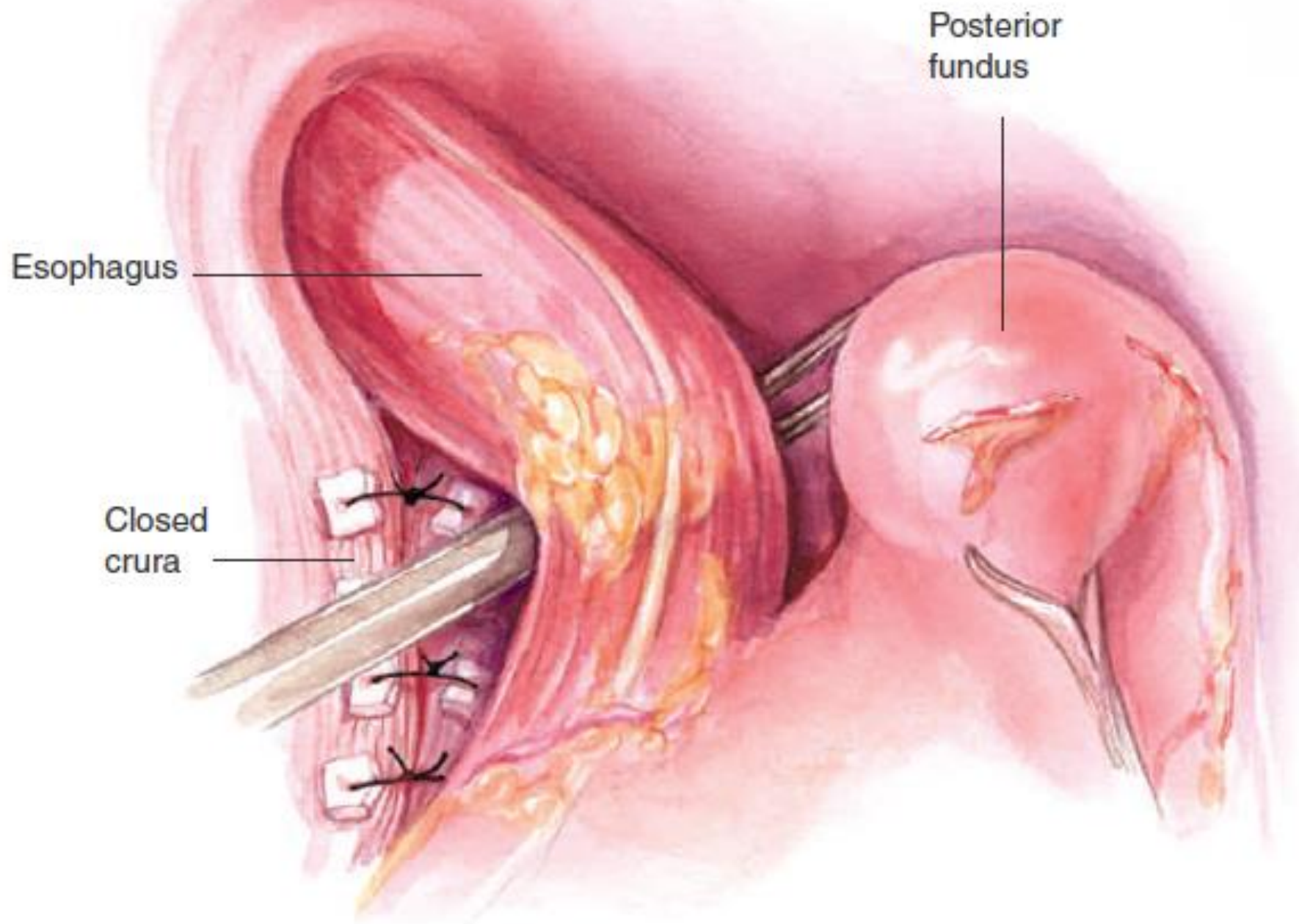
Esophagus
encircled

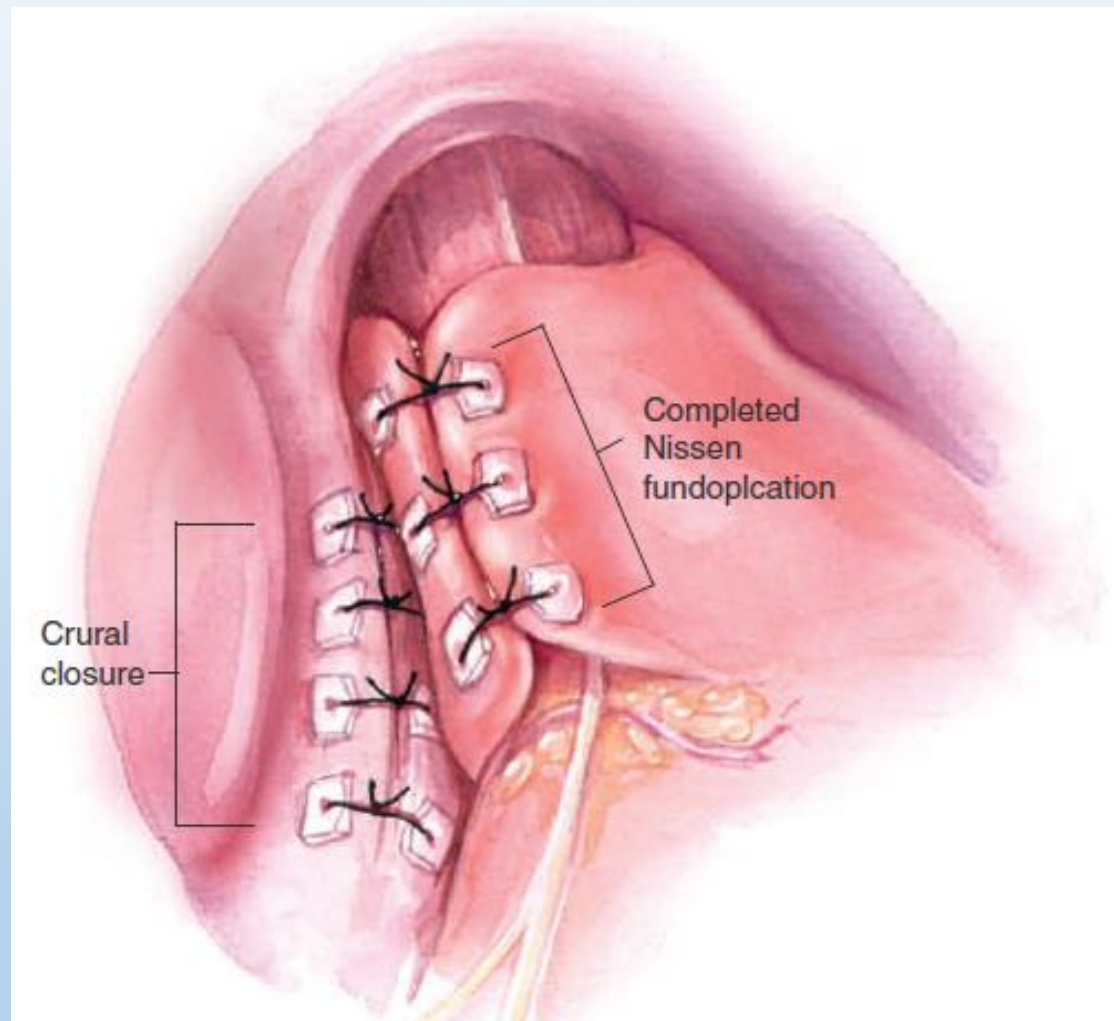
R. and l.
crura



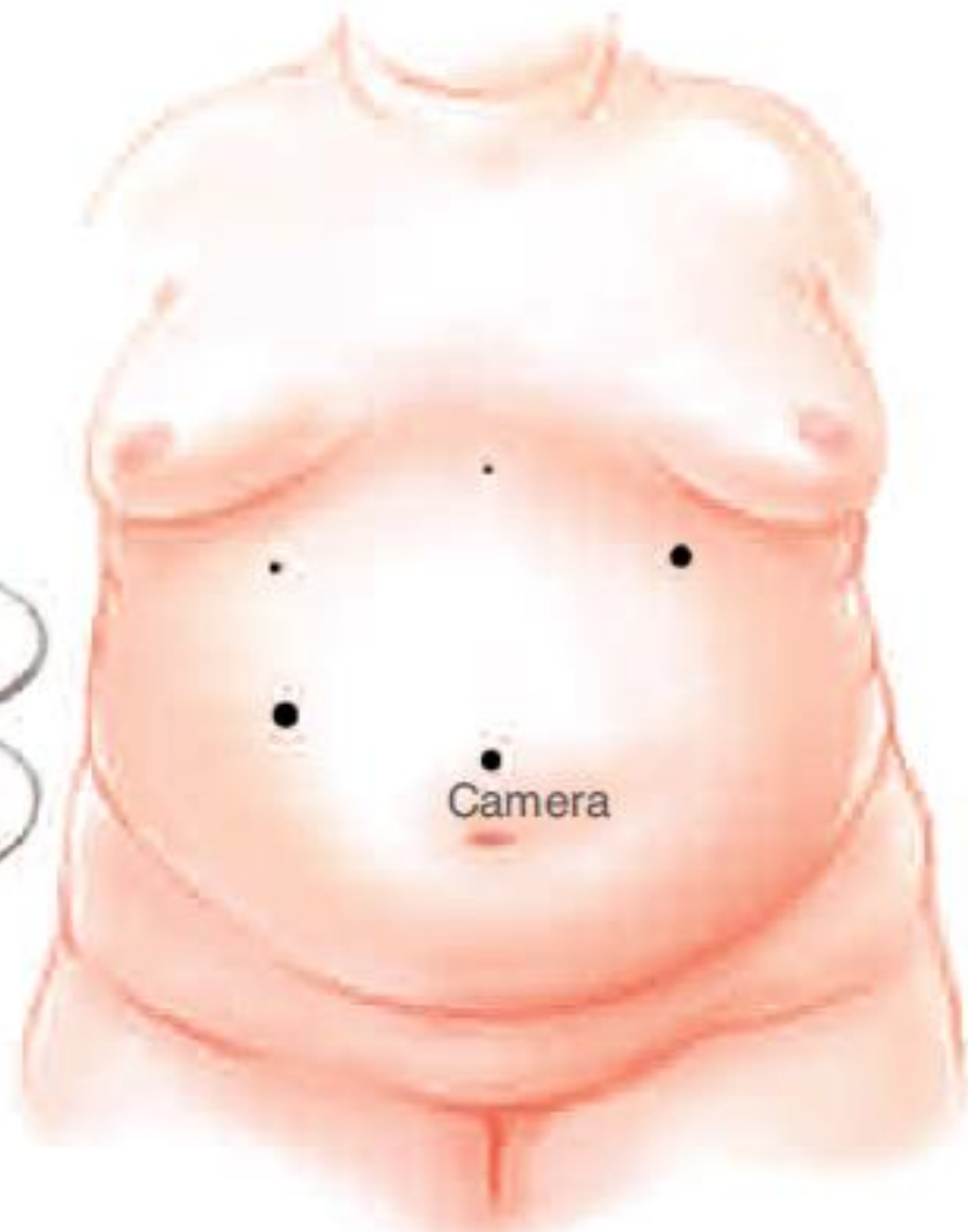
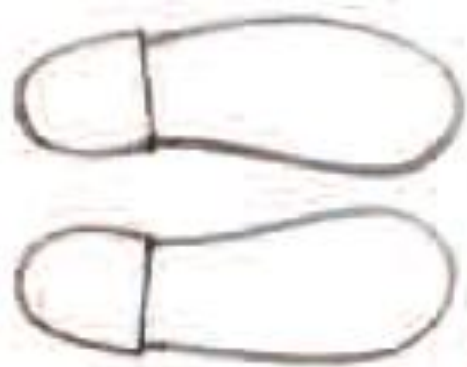
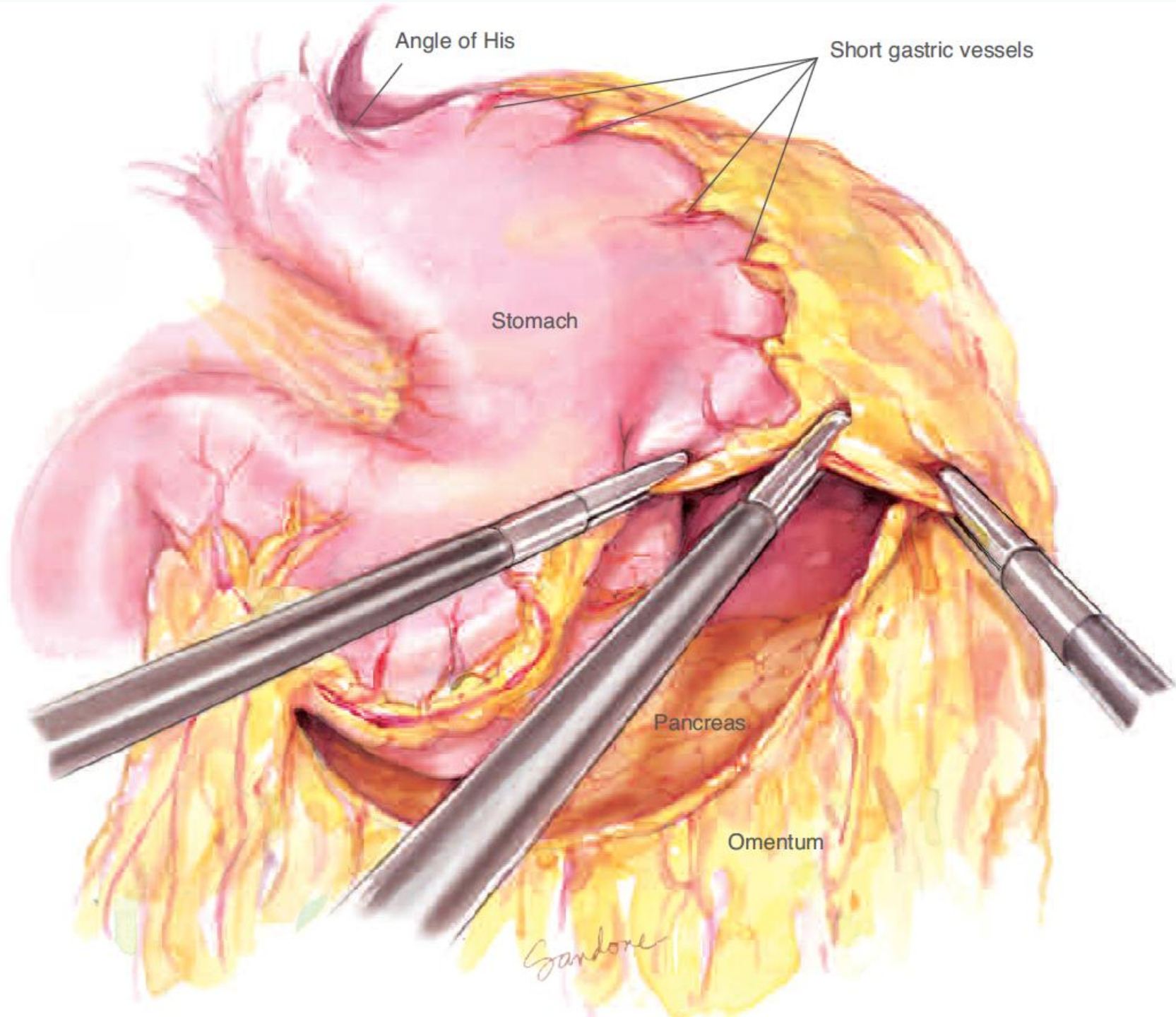
Crural
closure

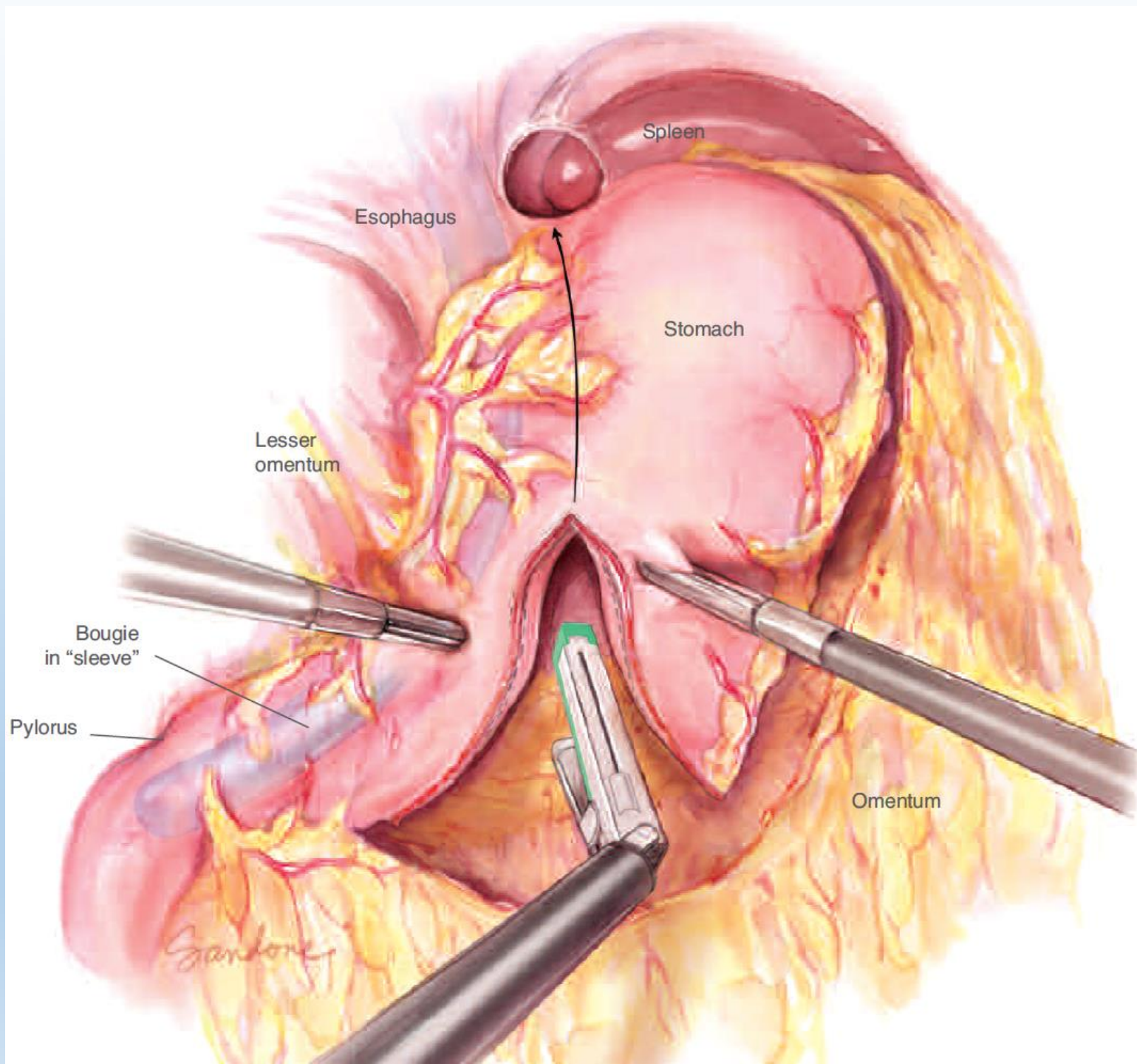


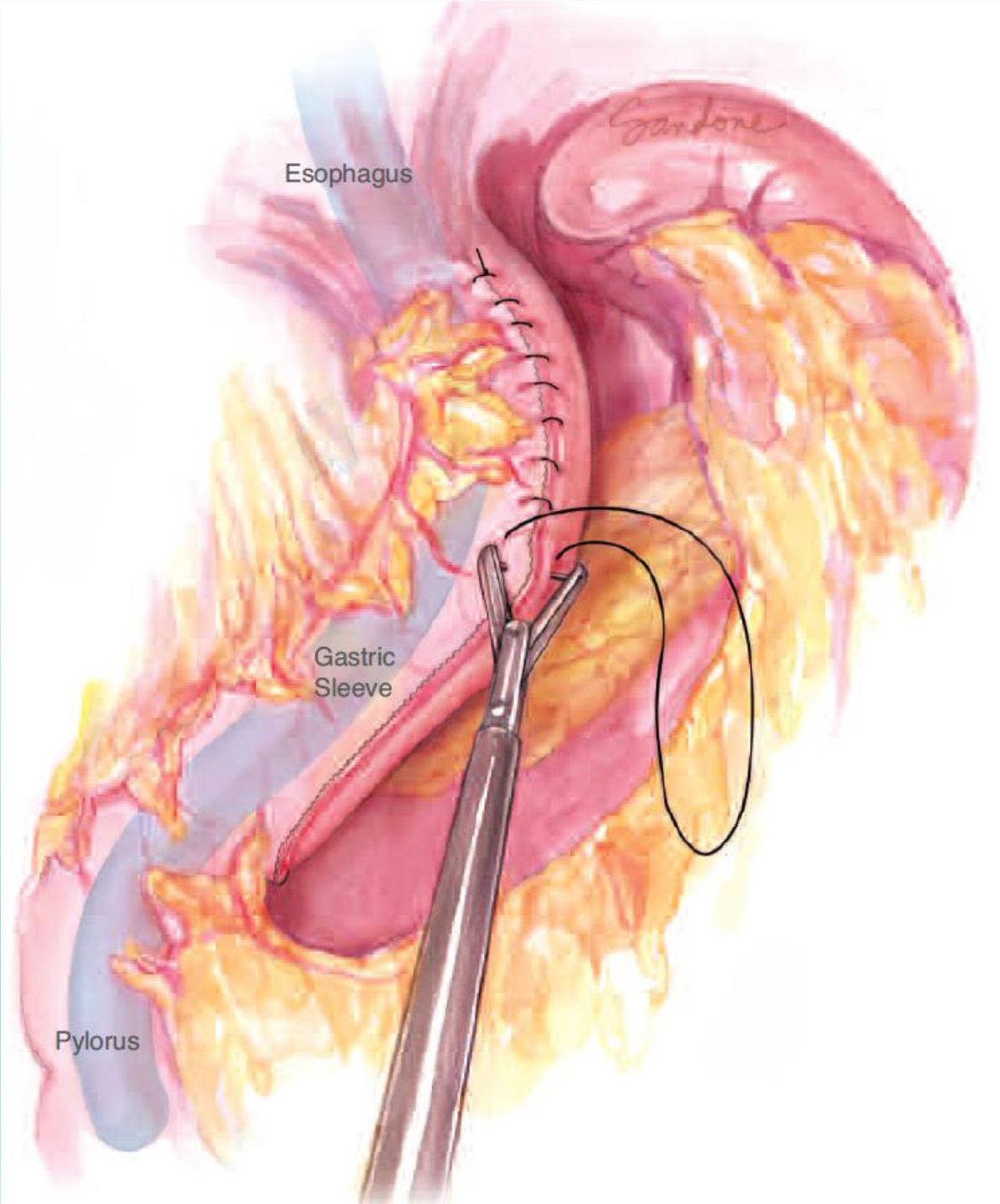


Sleeve Gastrectomy

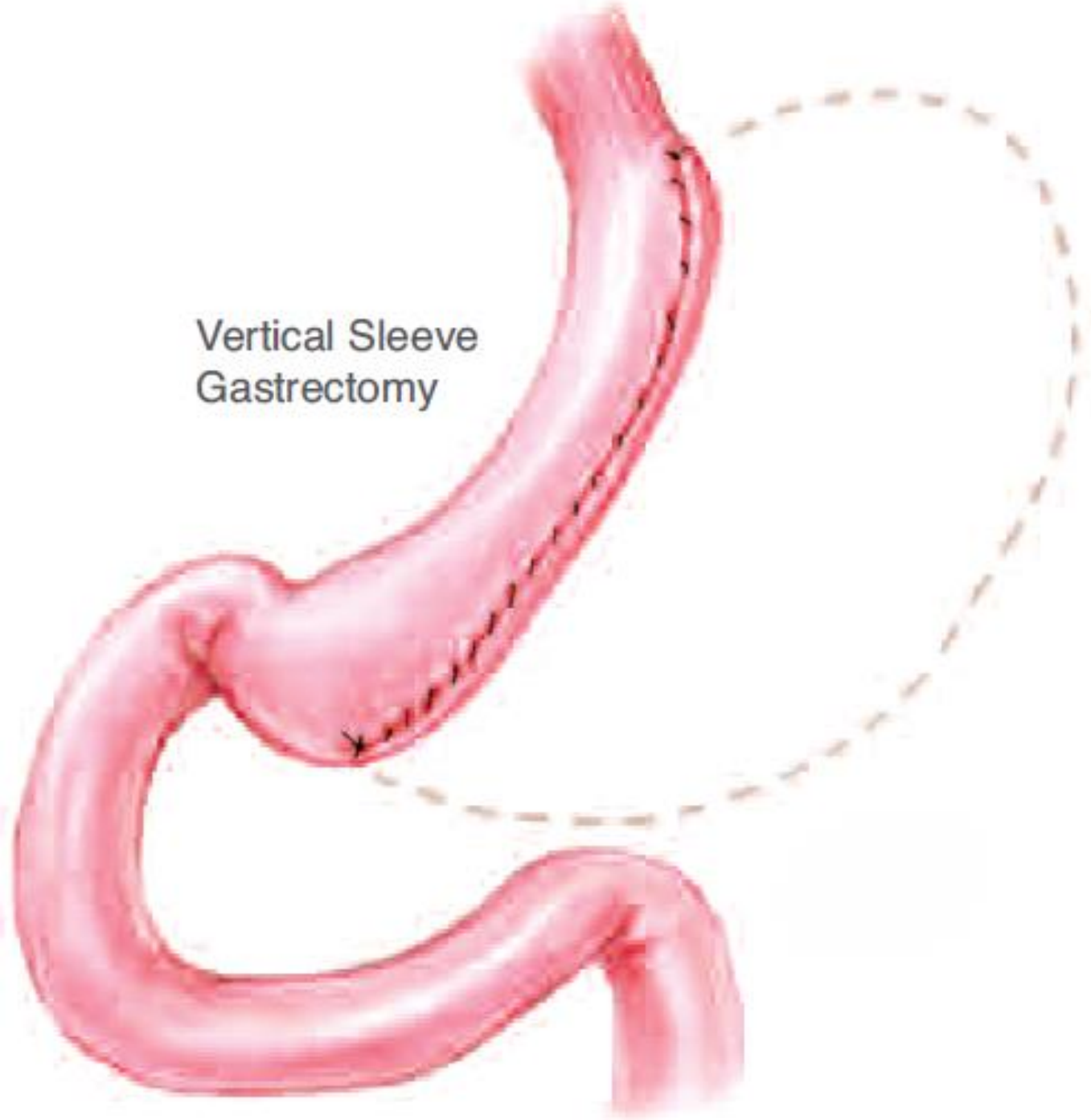



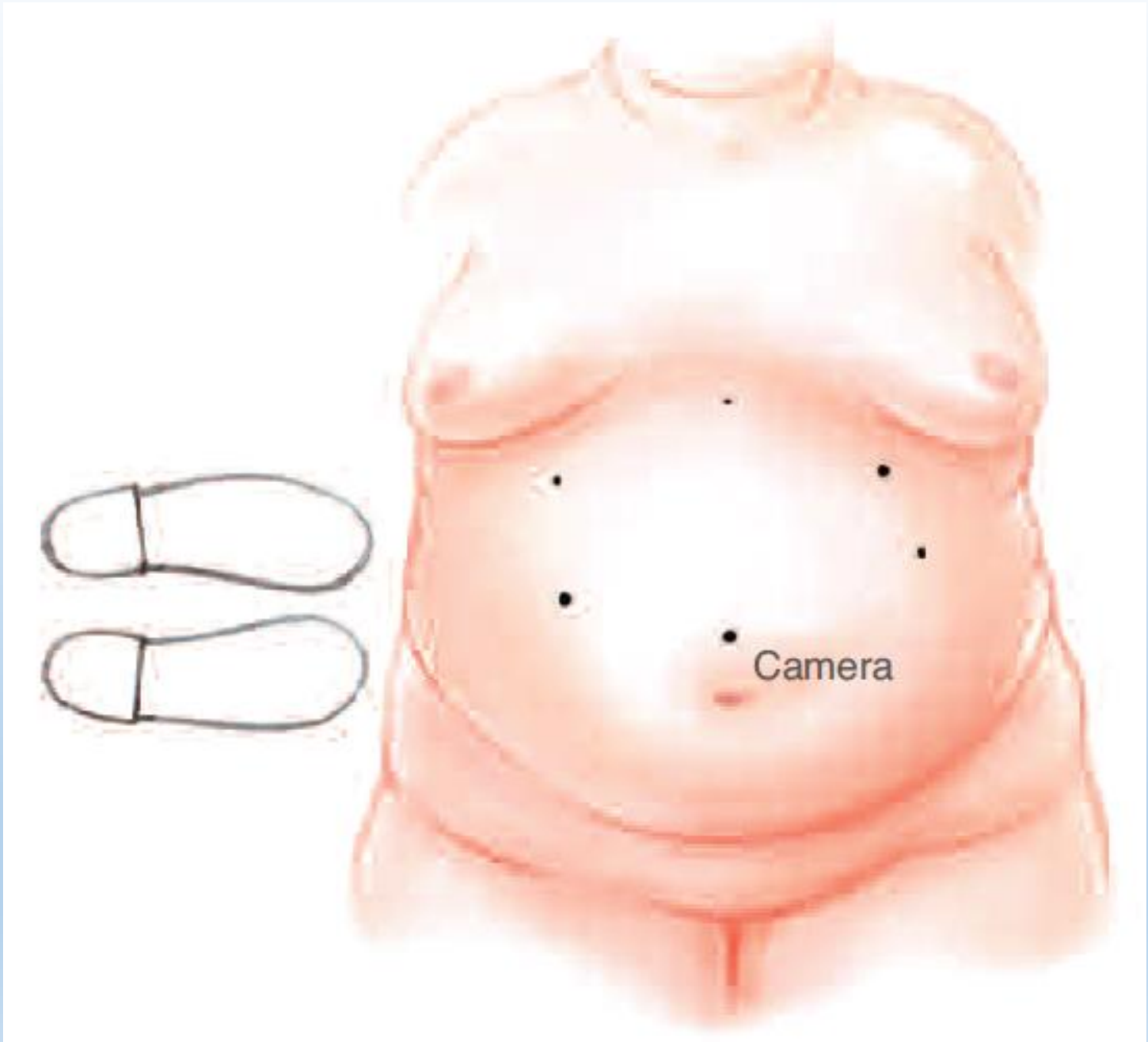


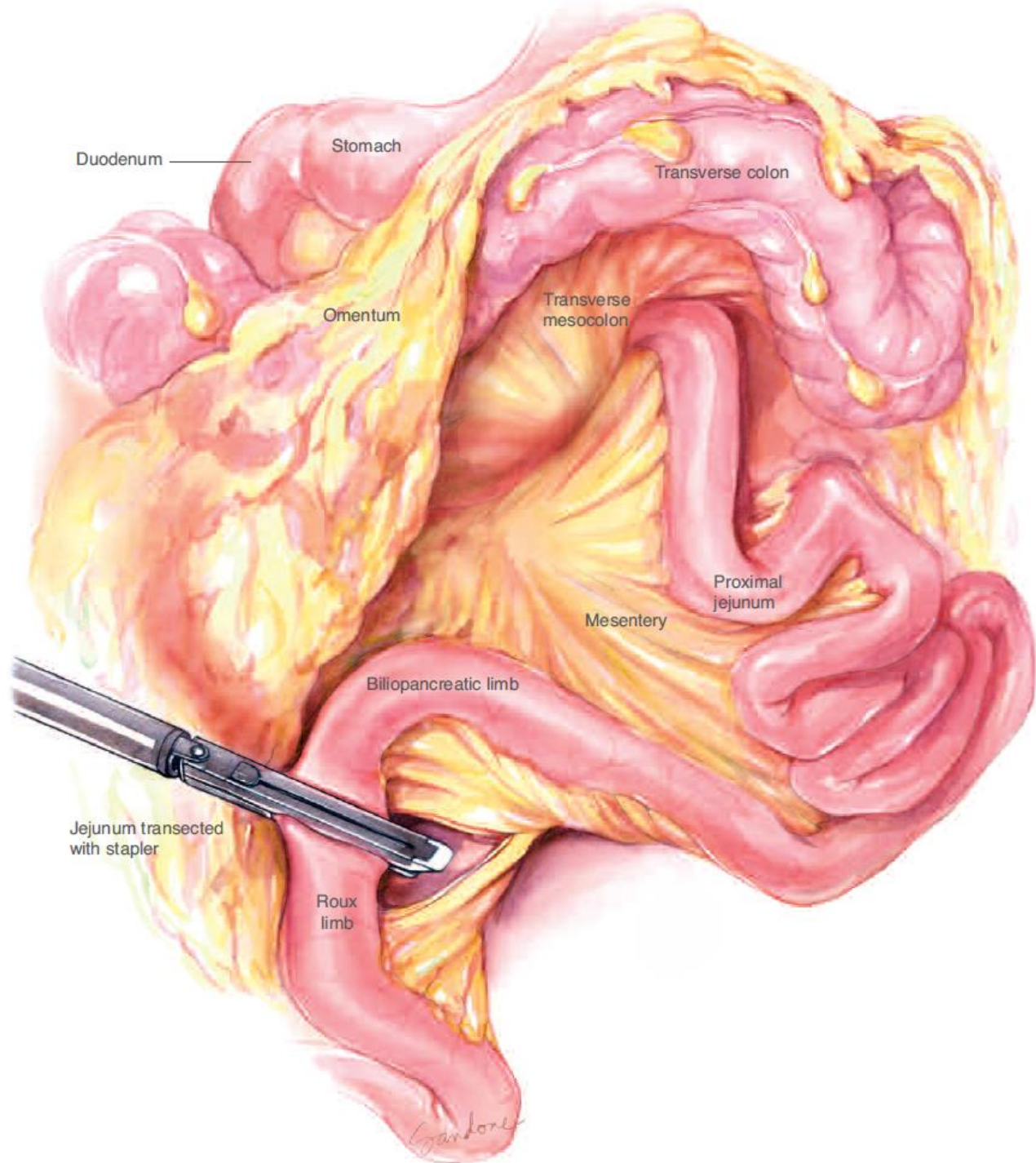


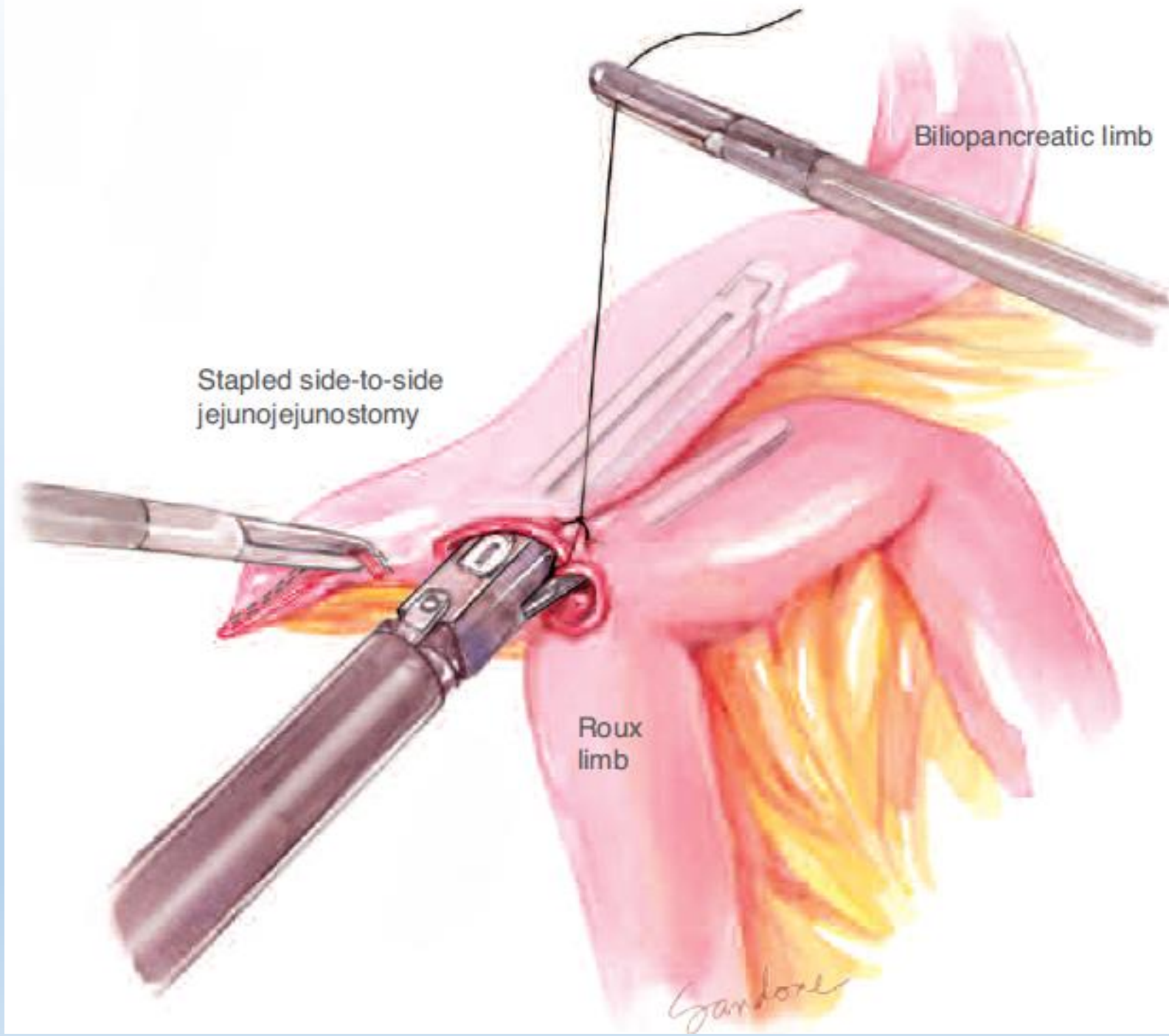
Vertical Sleeve
Gastrectomy

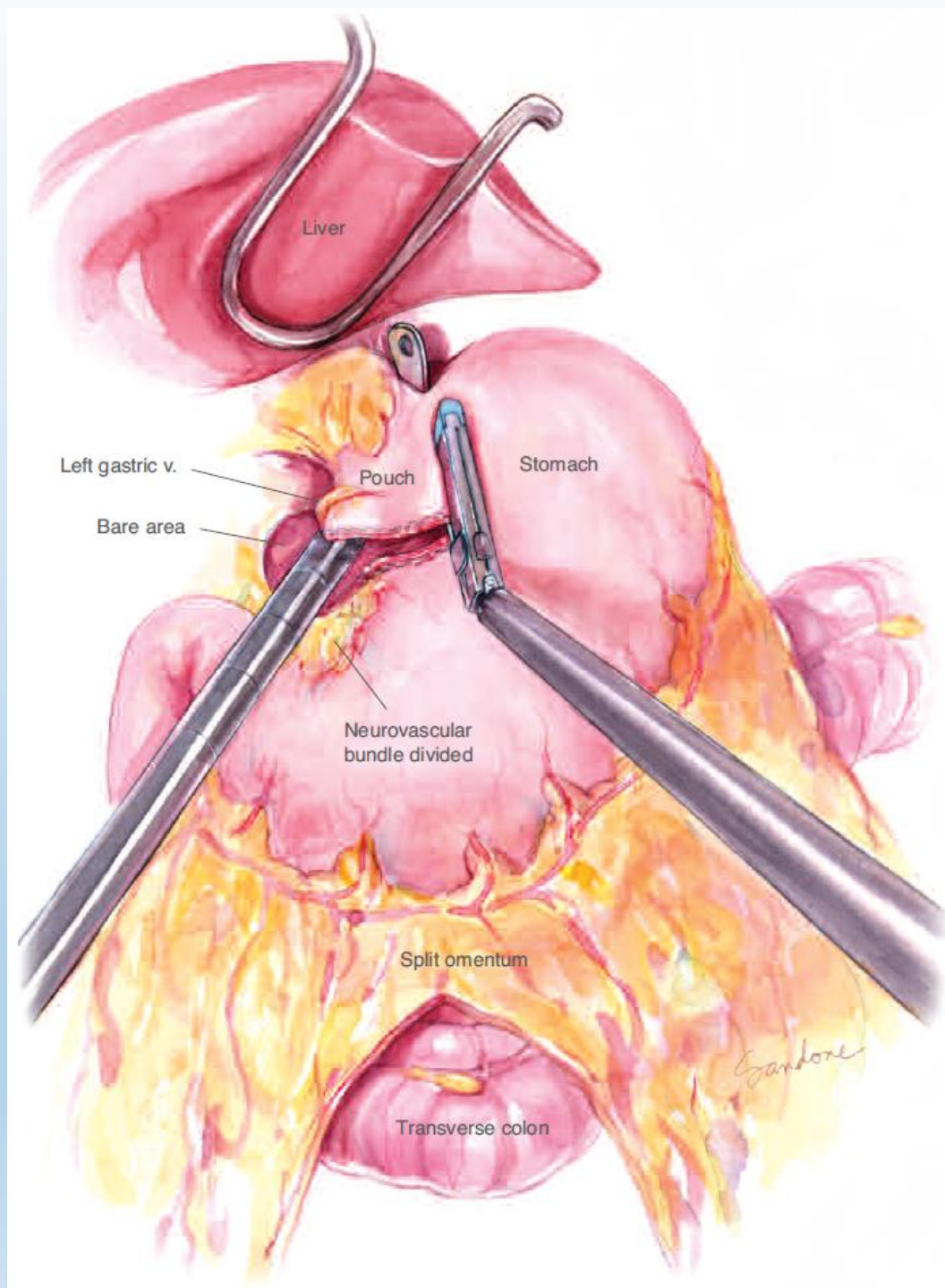


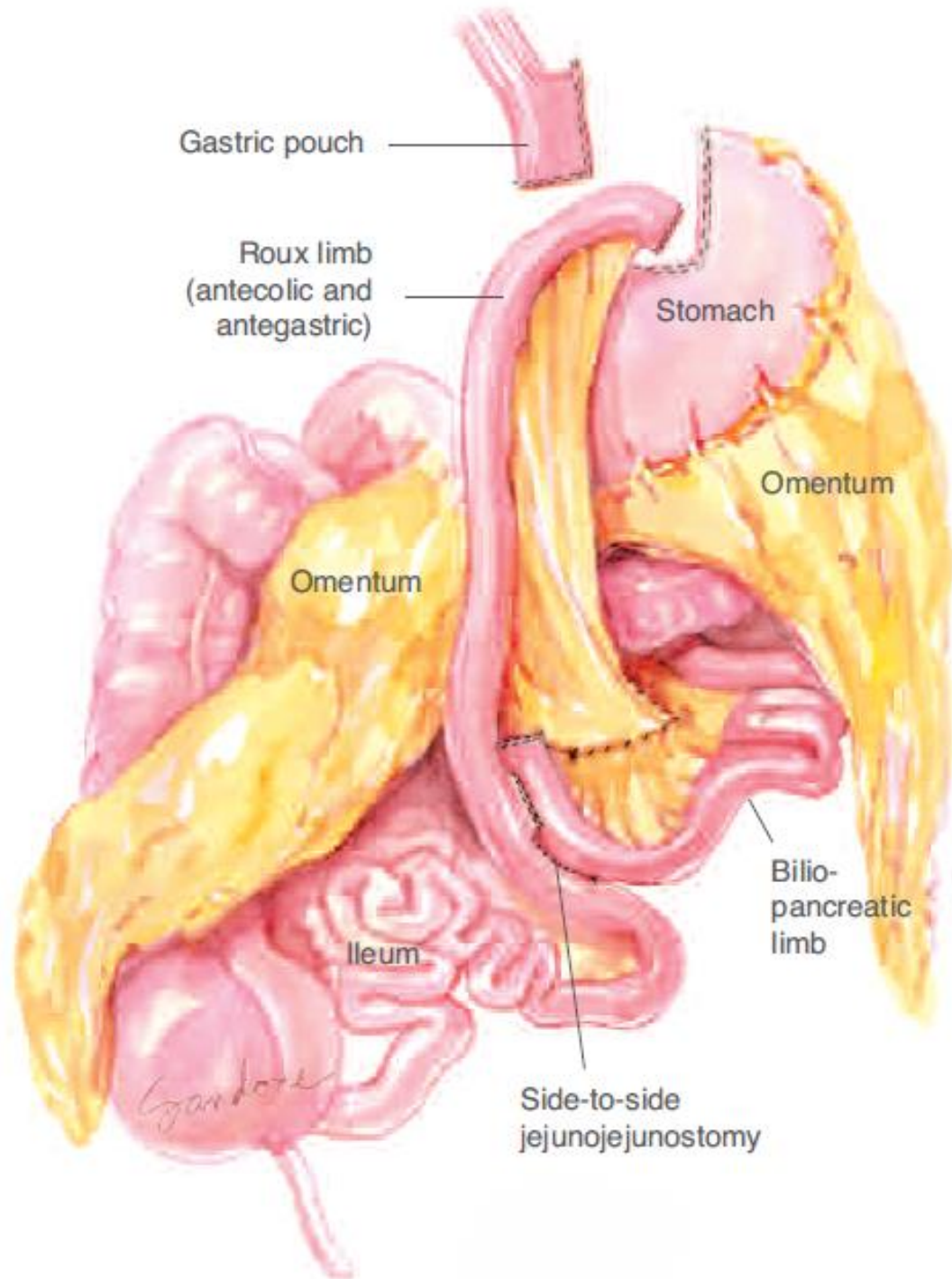
Roux-en-Y Gastric Bypass

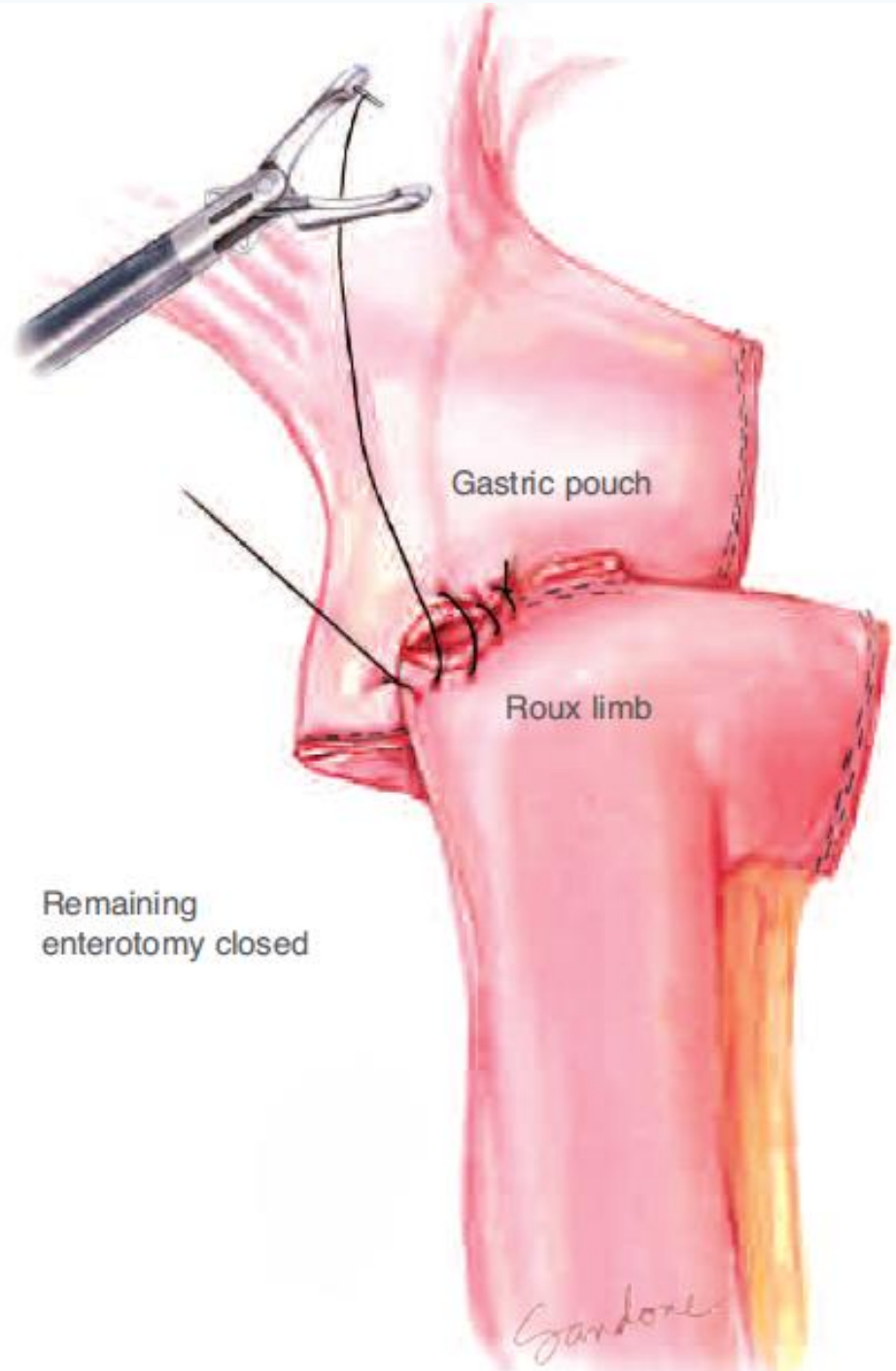




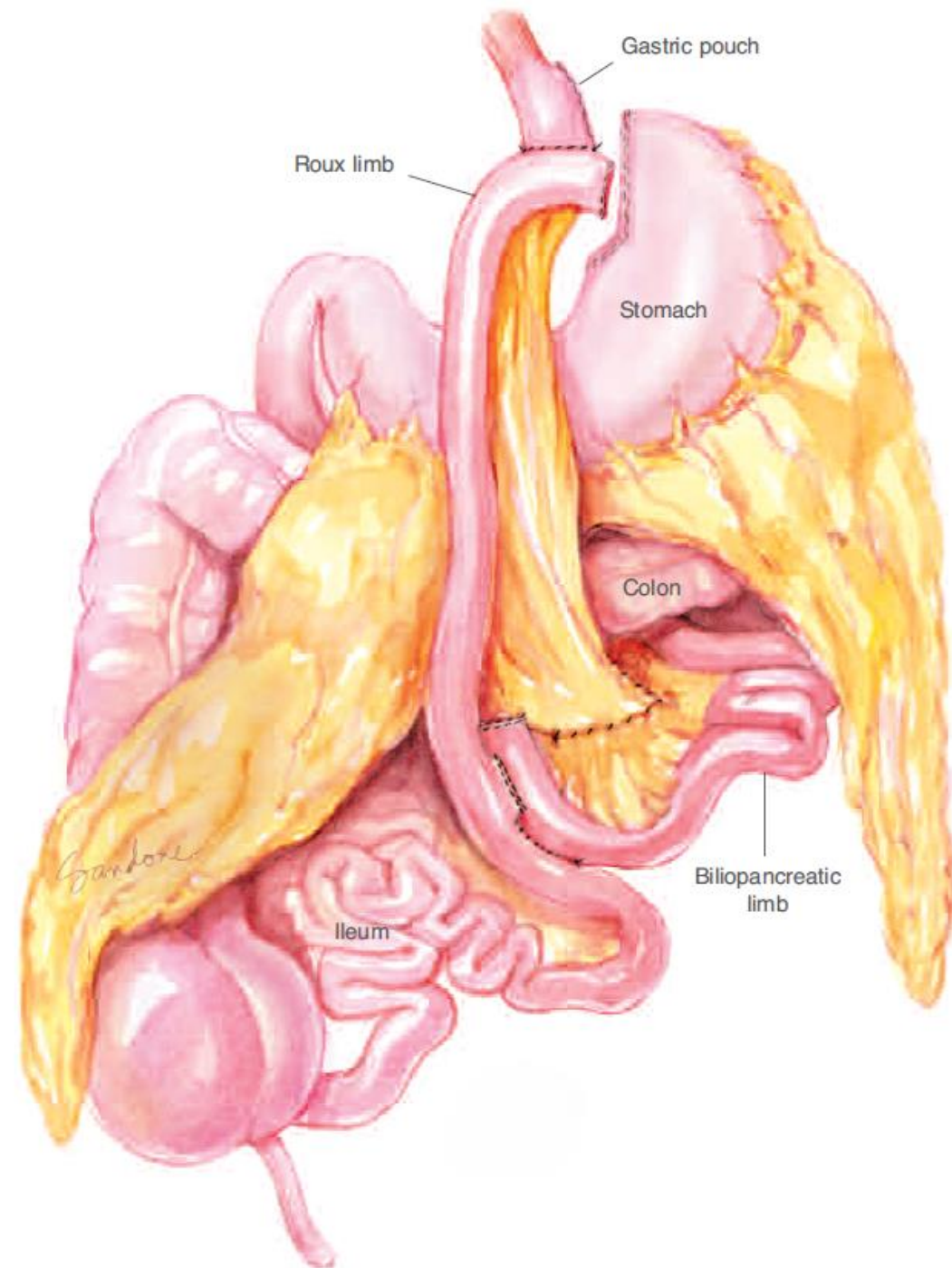




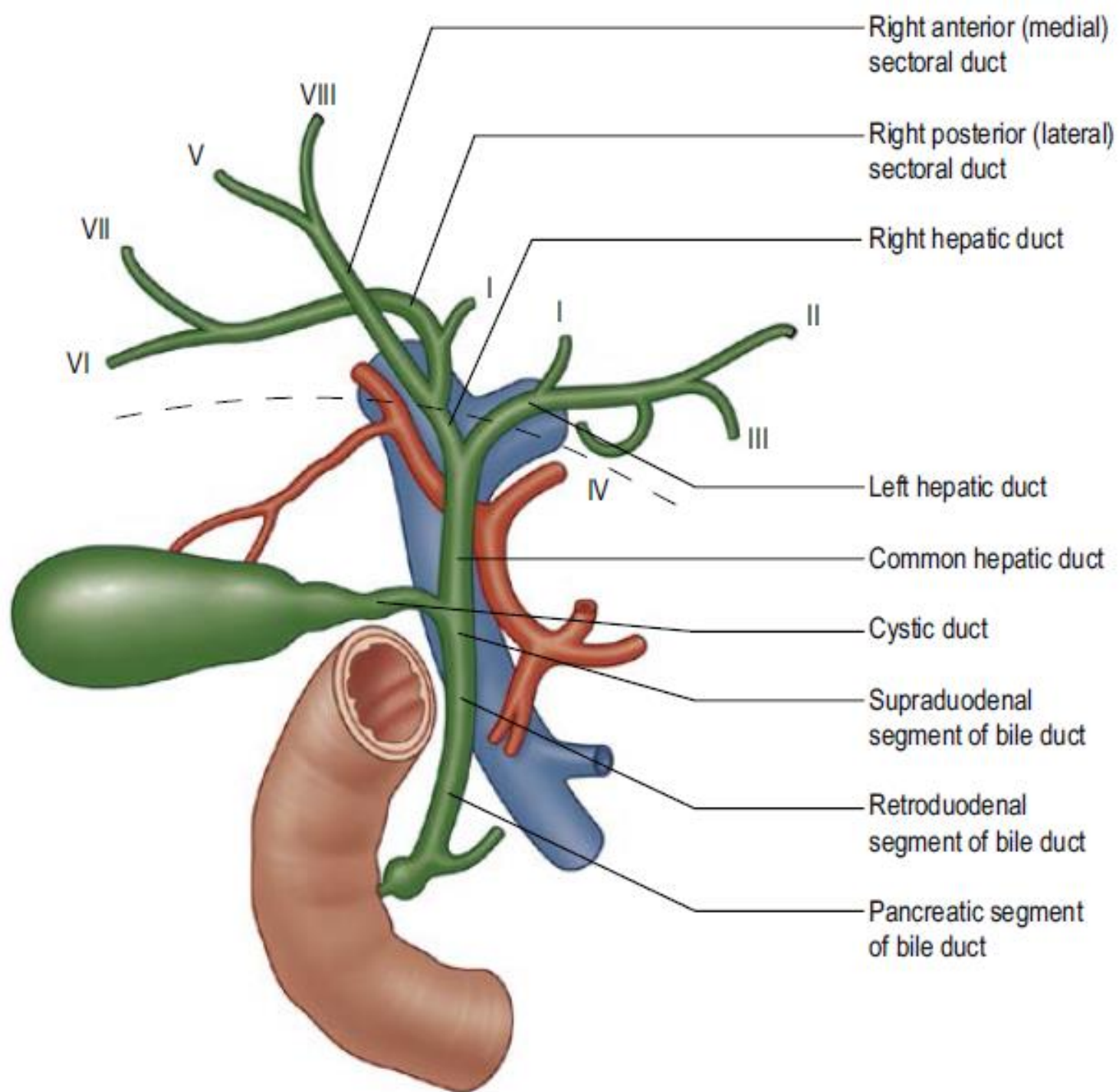




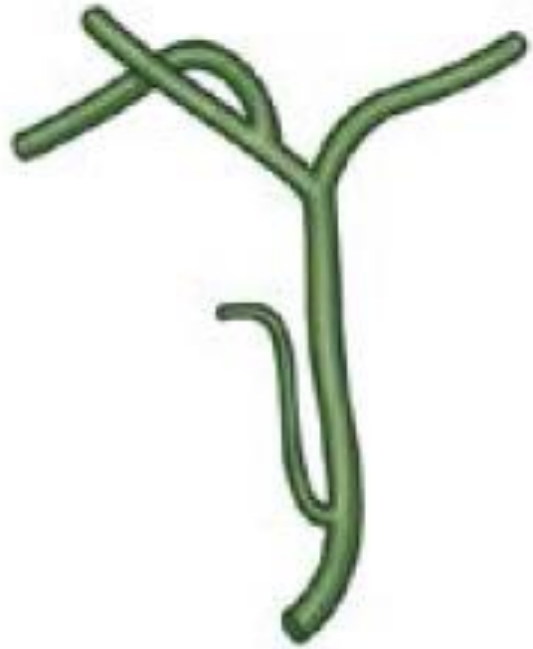Remaining enterotomy closed



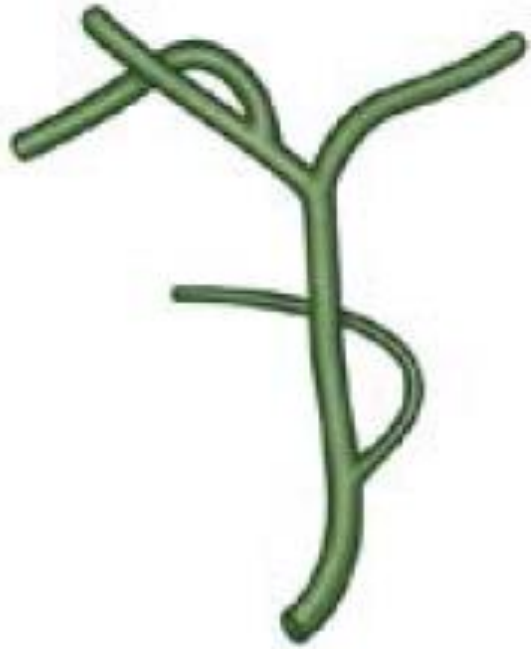Laparoscopic Cholecystectomy



Cystic duct variants



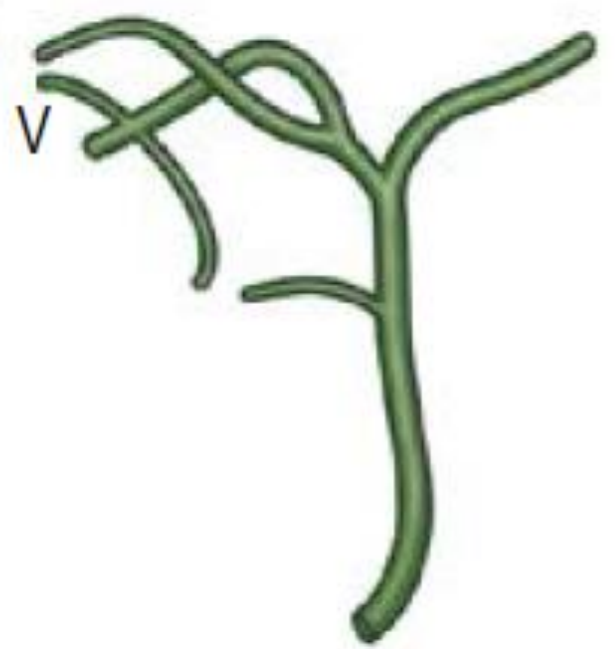
A1 Low entry



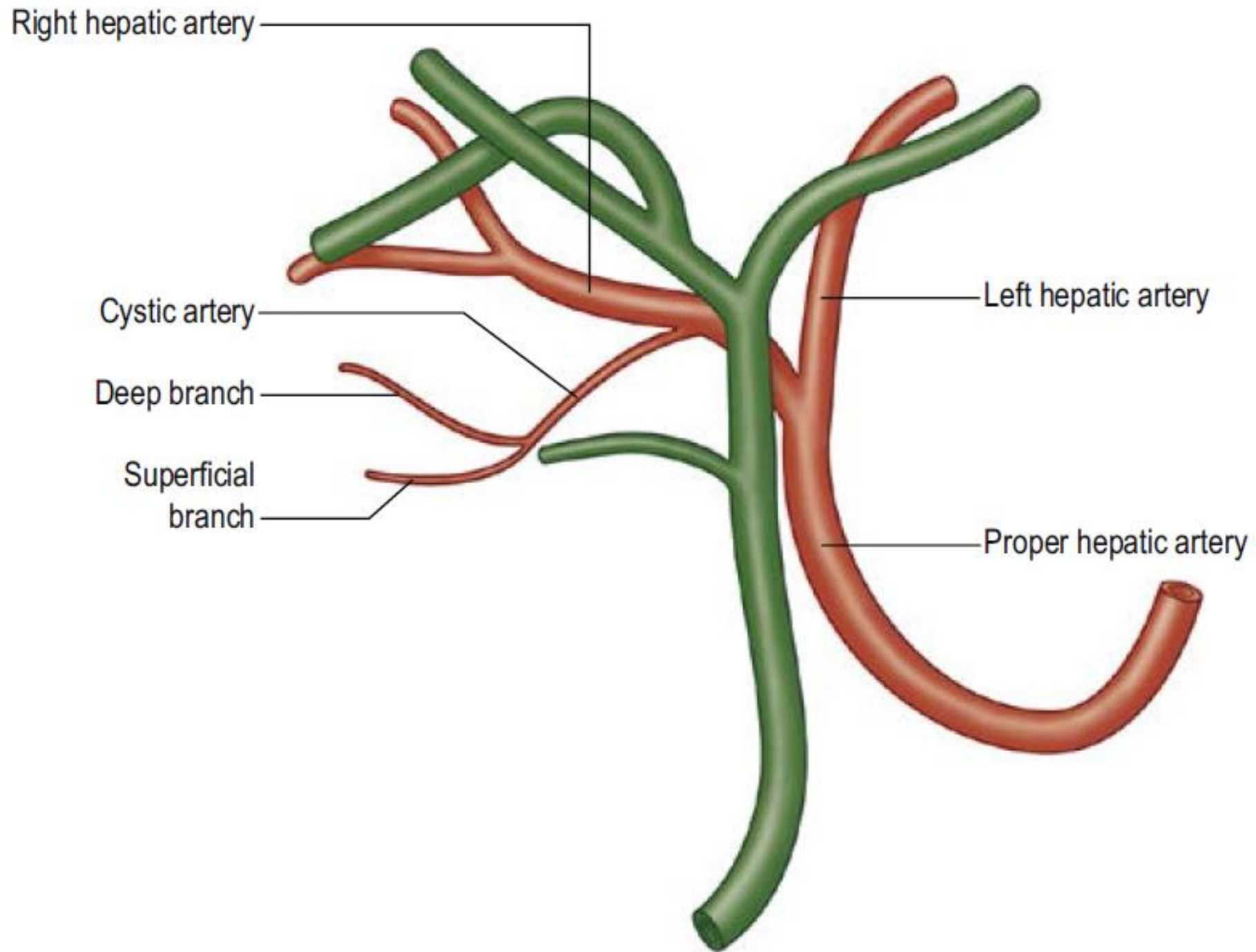
A2 Medial side entry

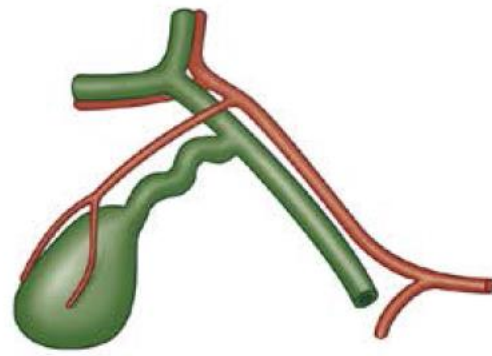


A3 Common drainage with right anterior sectoral duct

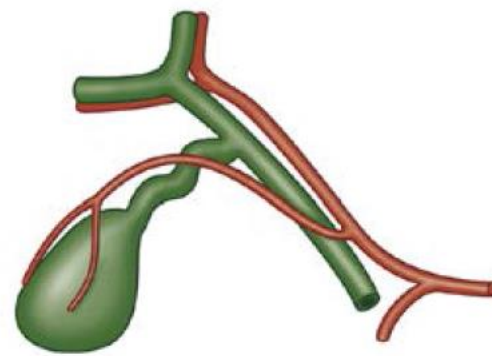


A4 Accessory bile duct (segment V) draining directly to gallbladder or cystic duct

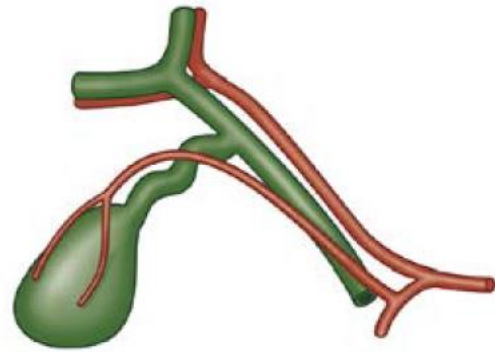




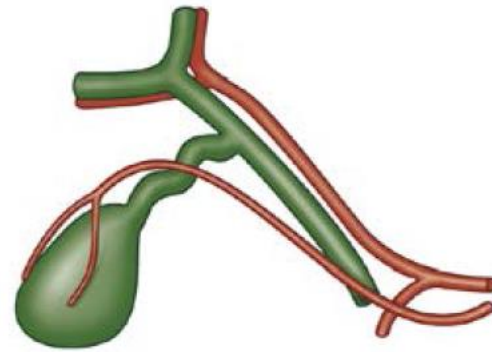
A Proper hepatic artery



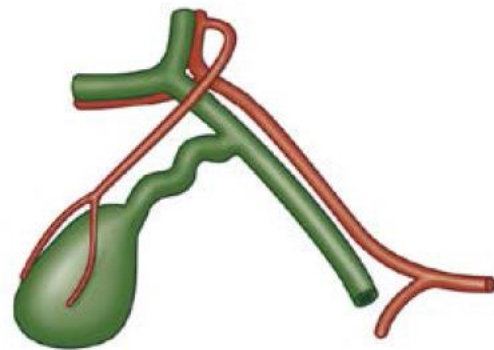
B Low origin from proper hepatic artery



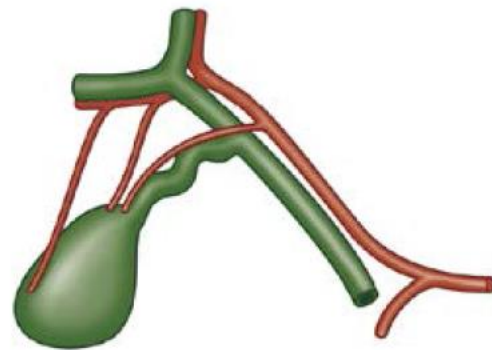
C Gastroduodenal artery



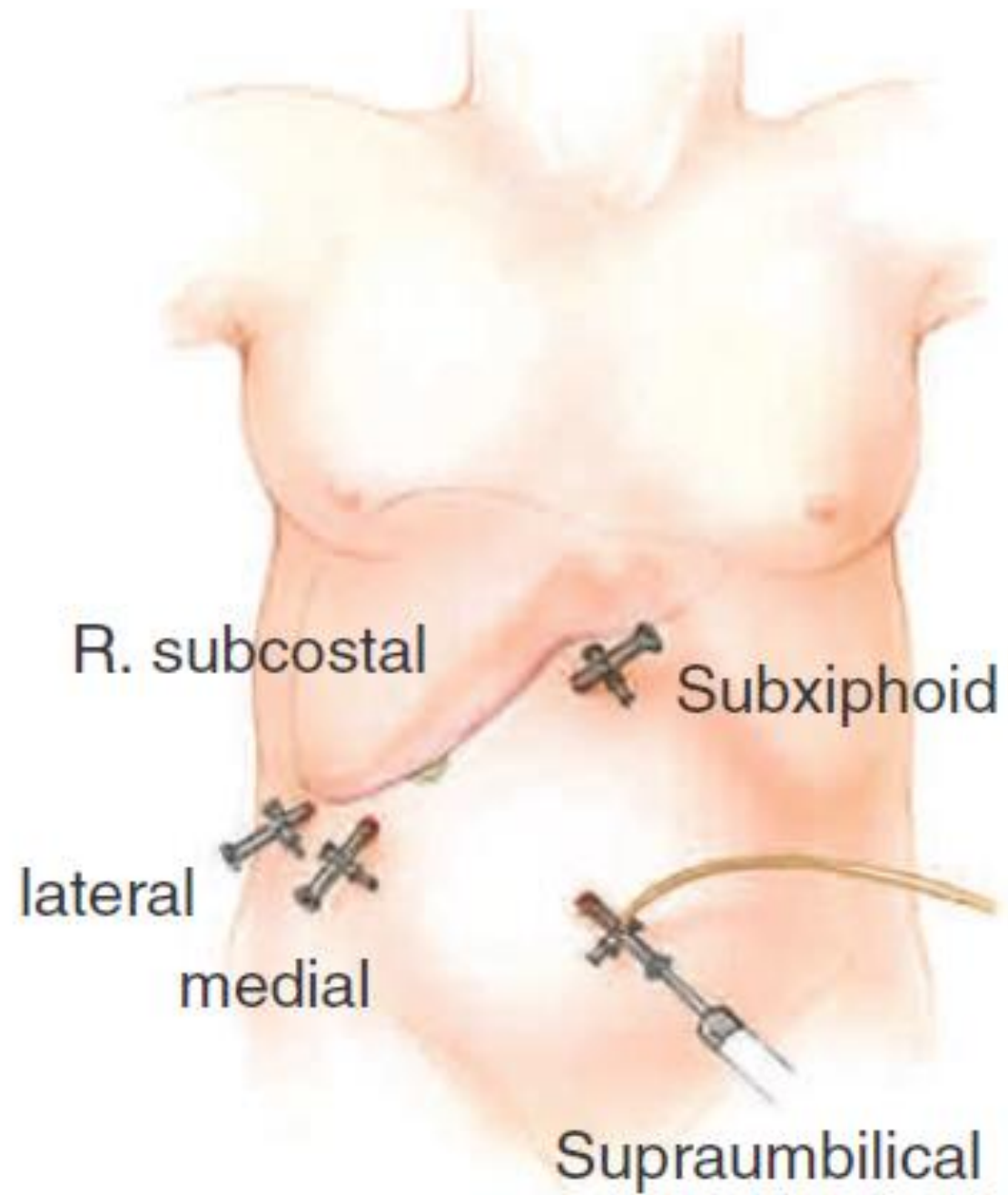
D Superior pancreaticoduodenal,
coeliac trunk or right gastric artery

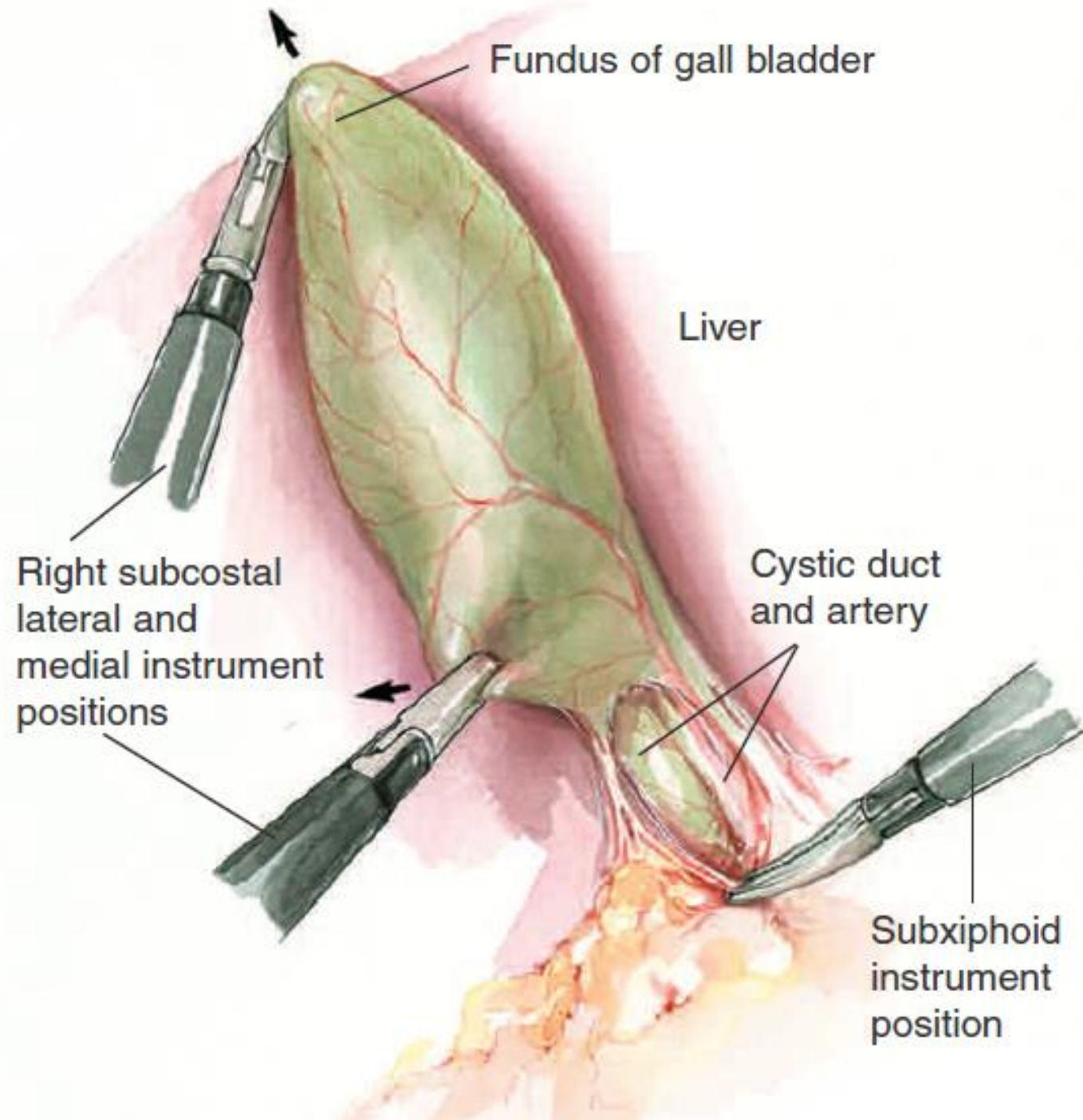


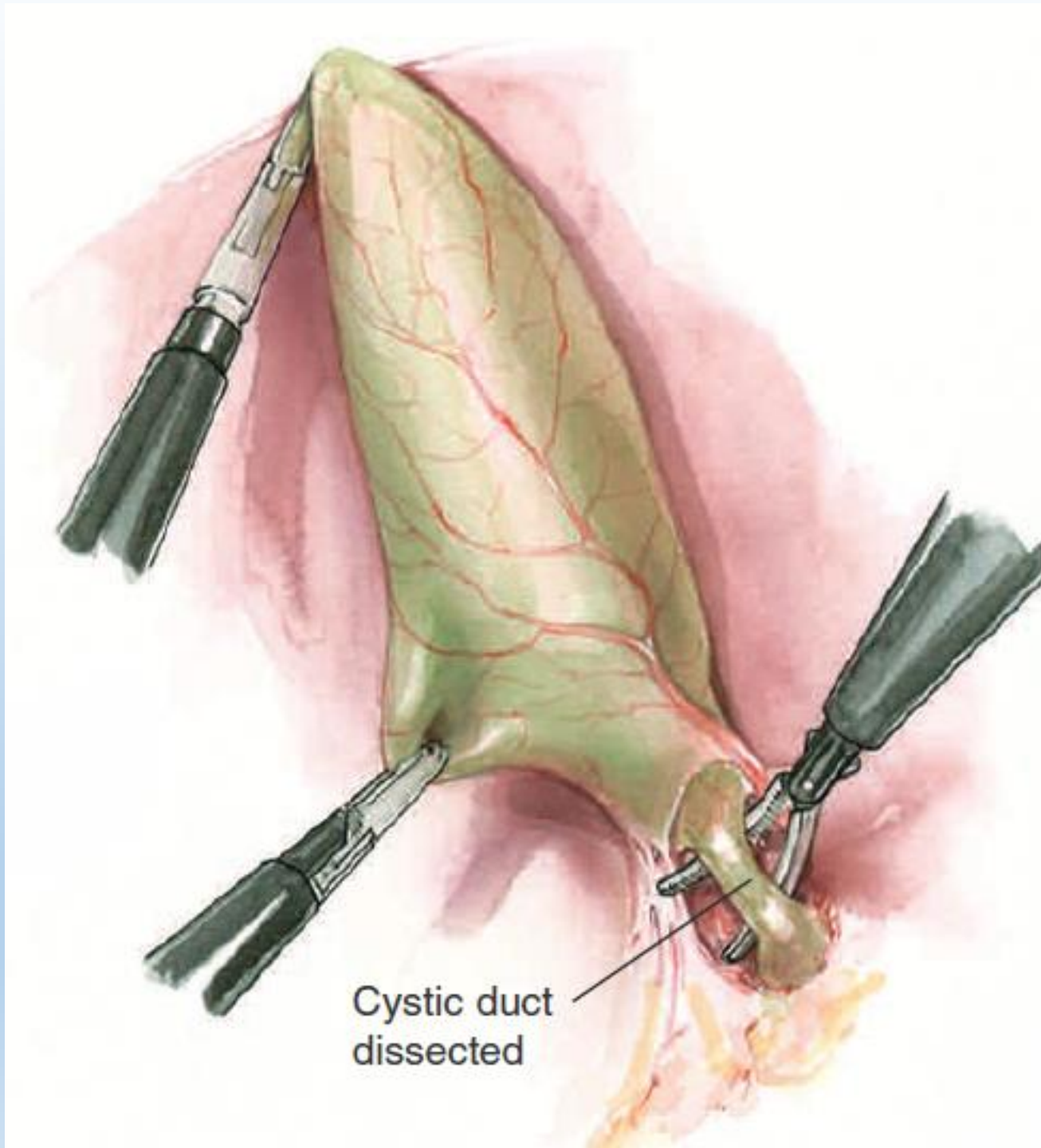
E Left hepatic artery



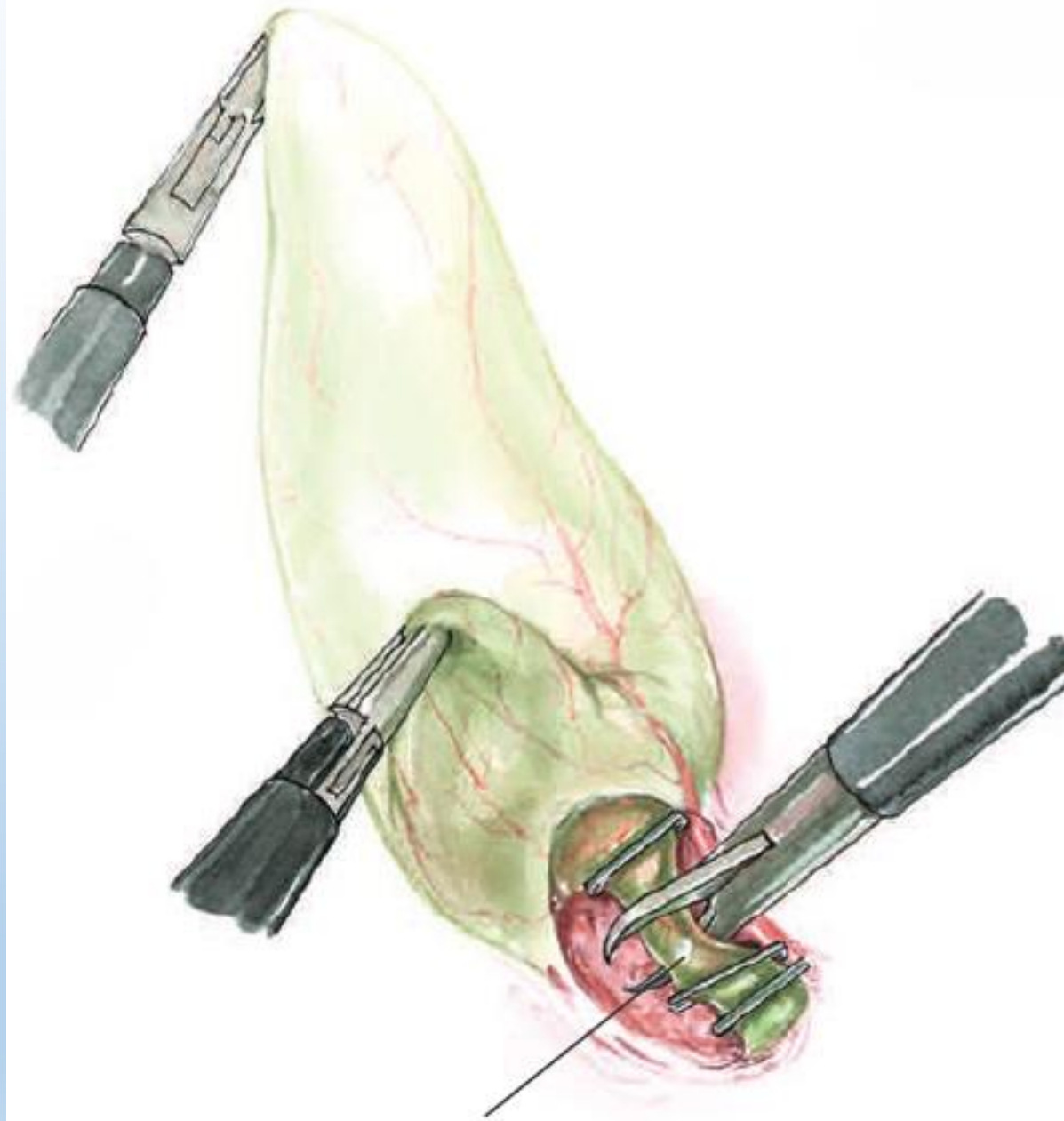
F Multiple cystic arteries



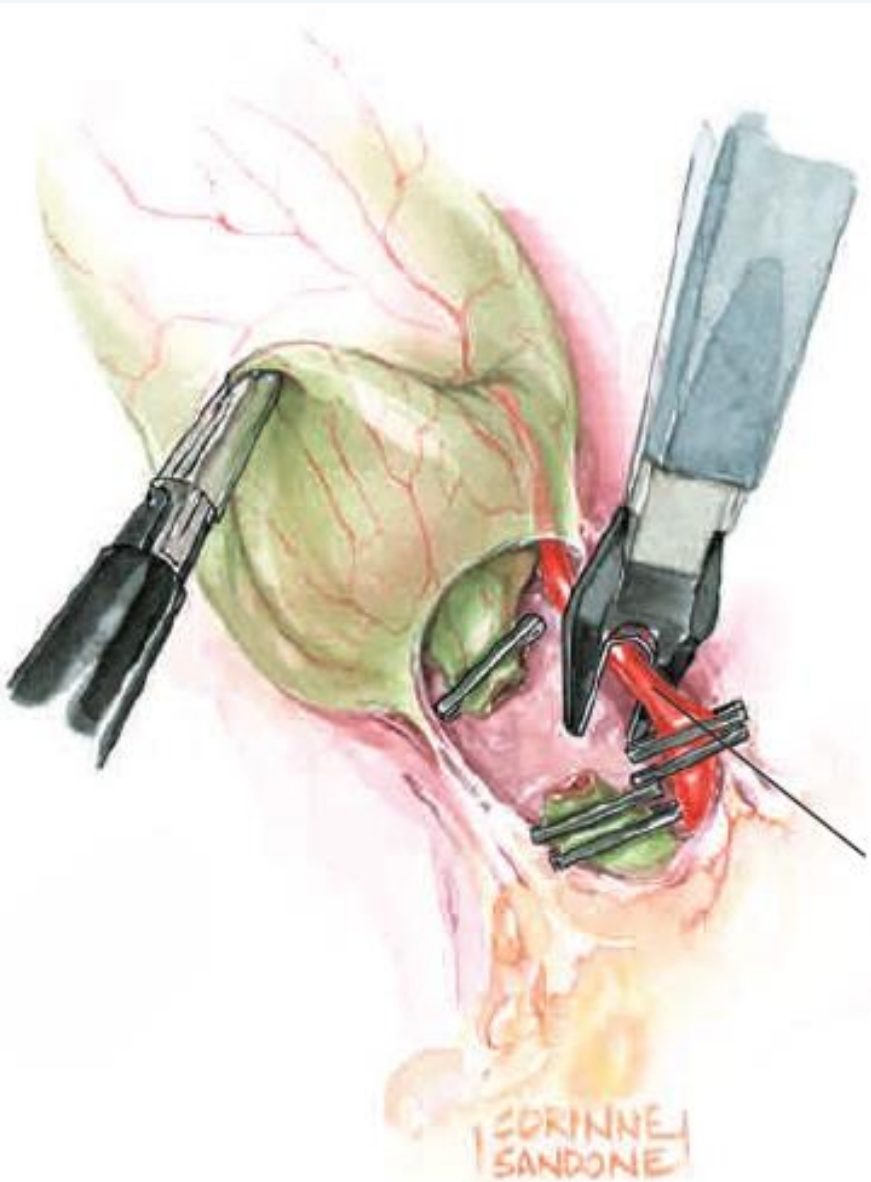



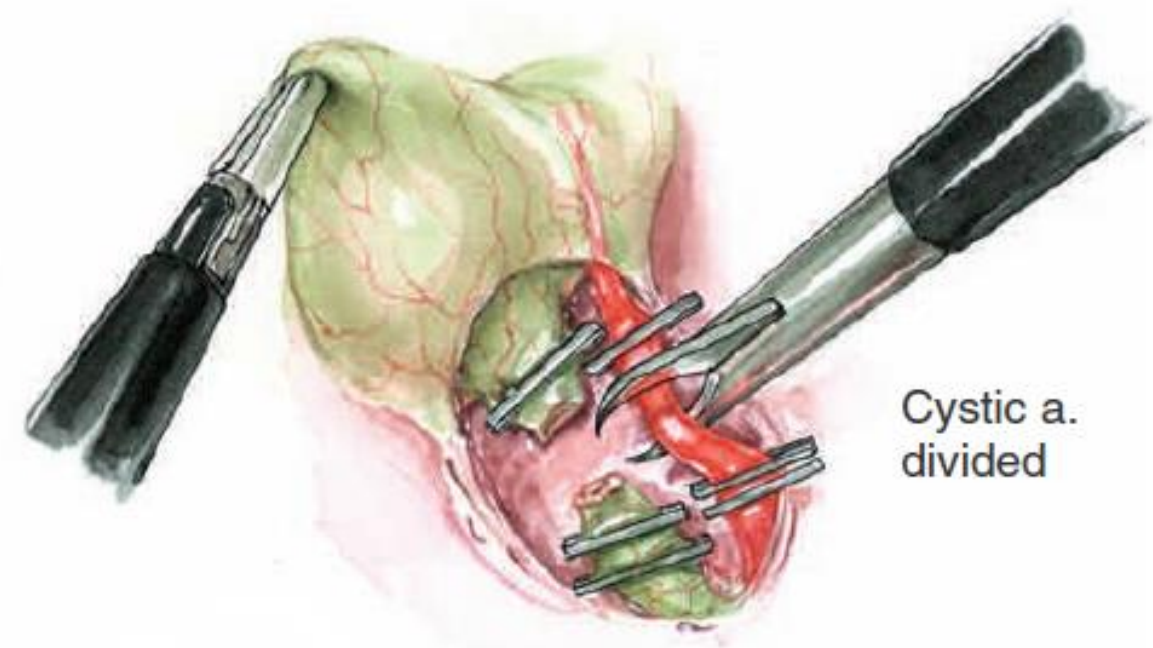Cystic duct
dissected



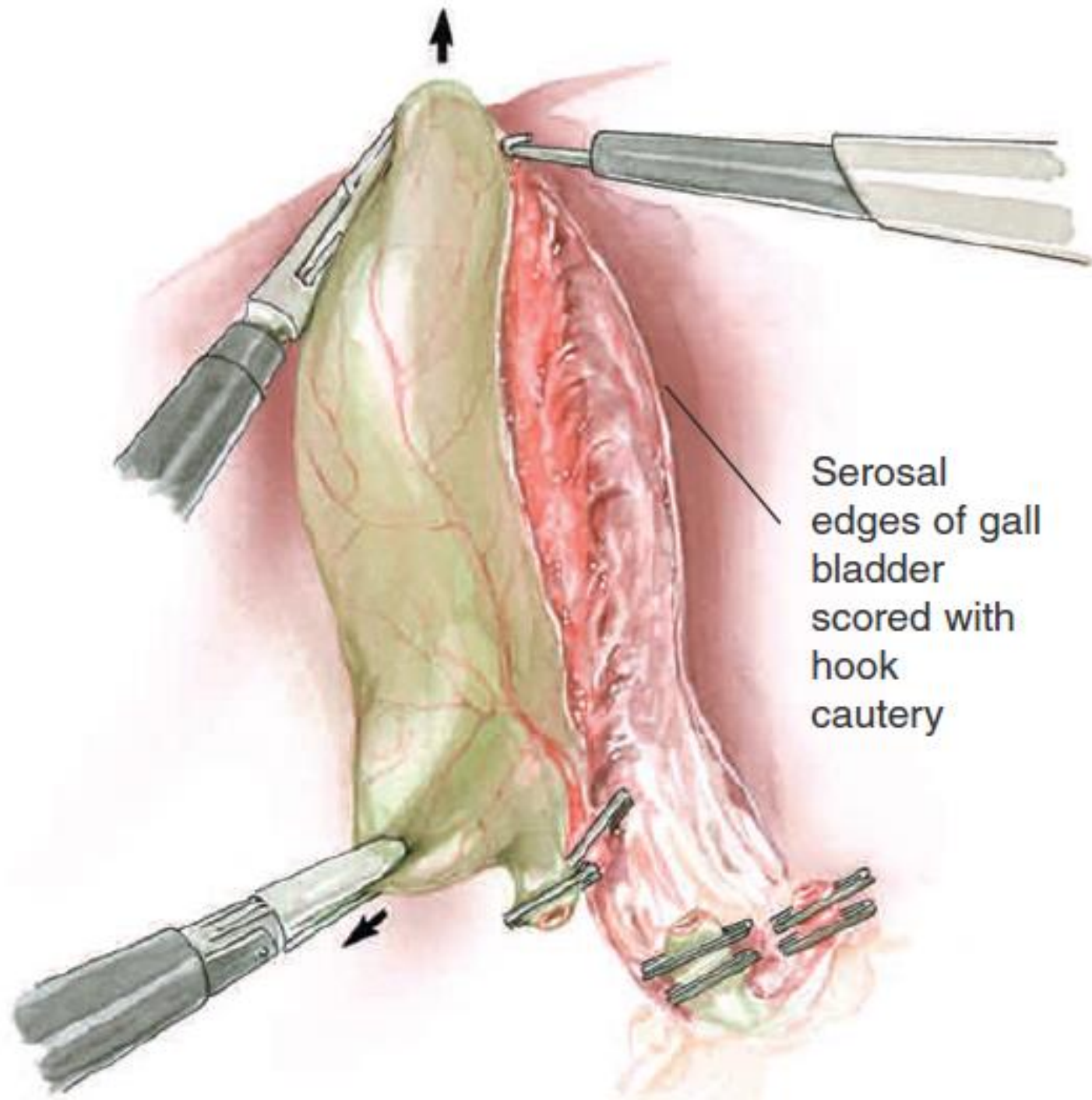
Cystic duct stapled
distally and divided



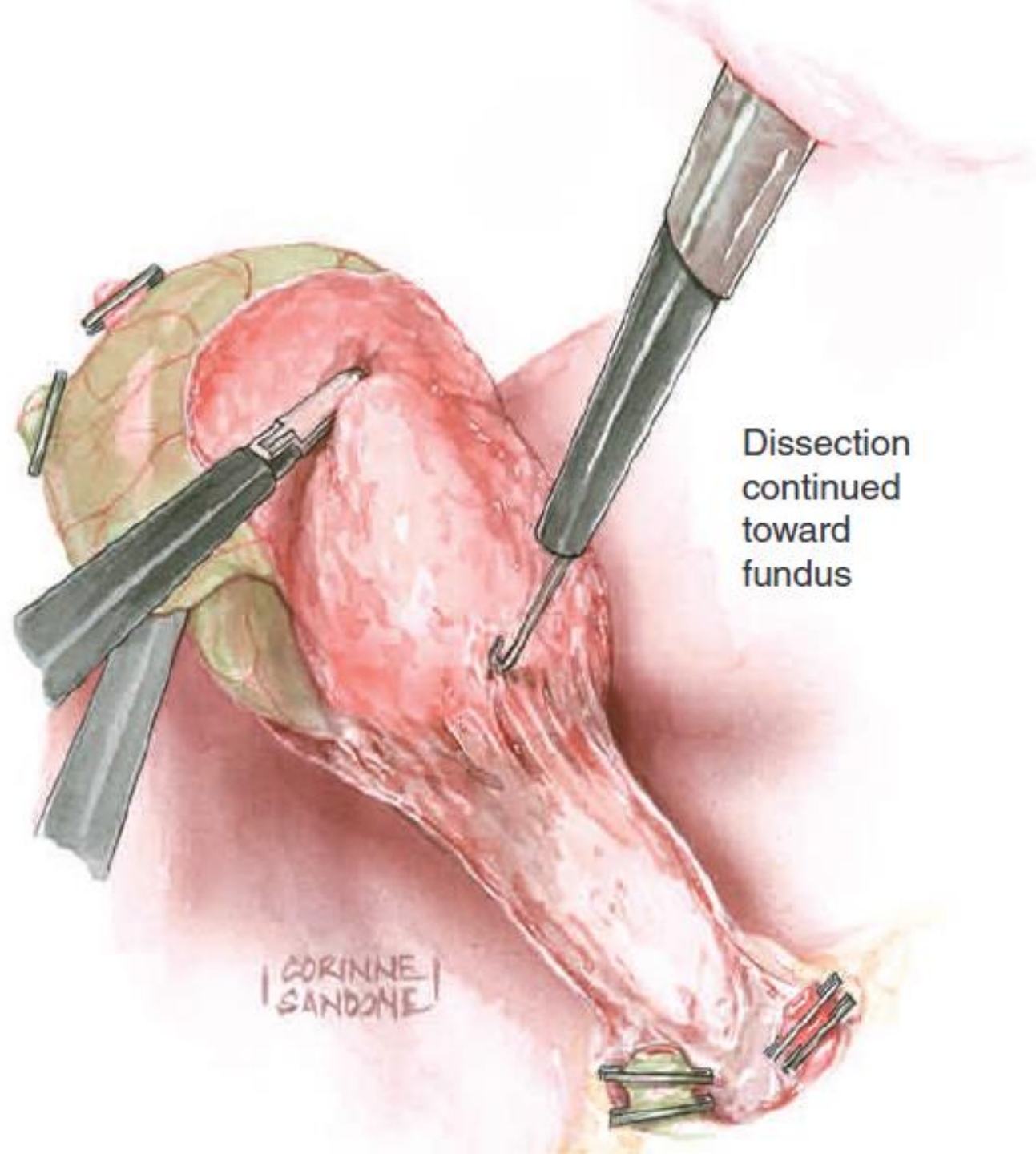
Cystic a. clipped



Cystic a. divided

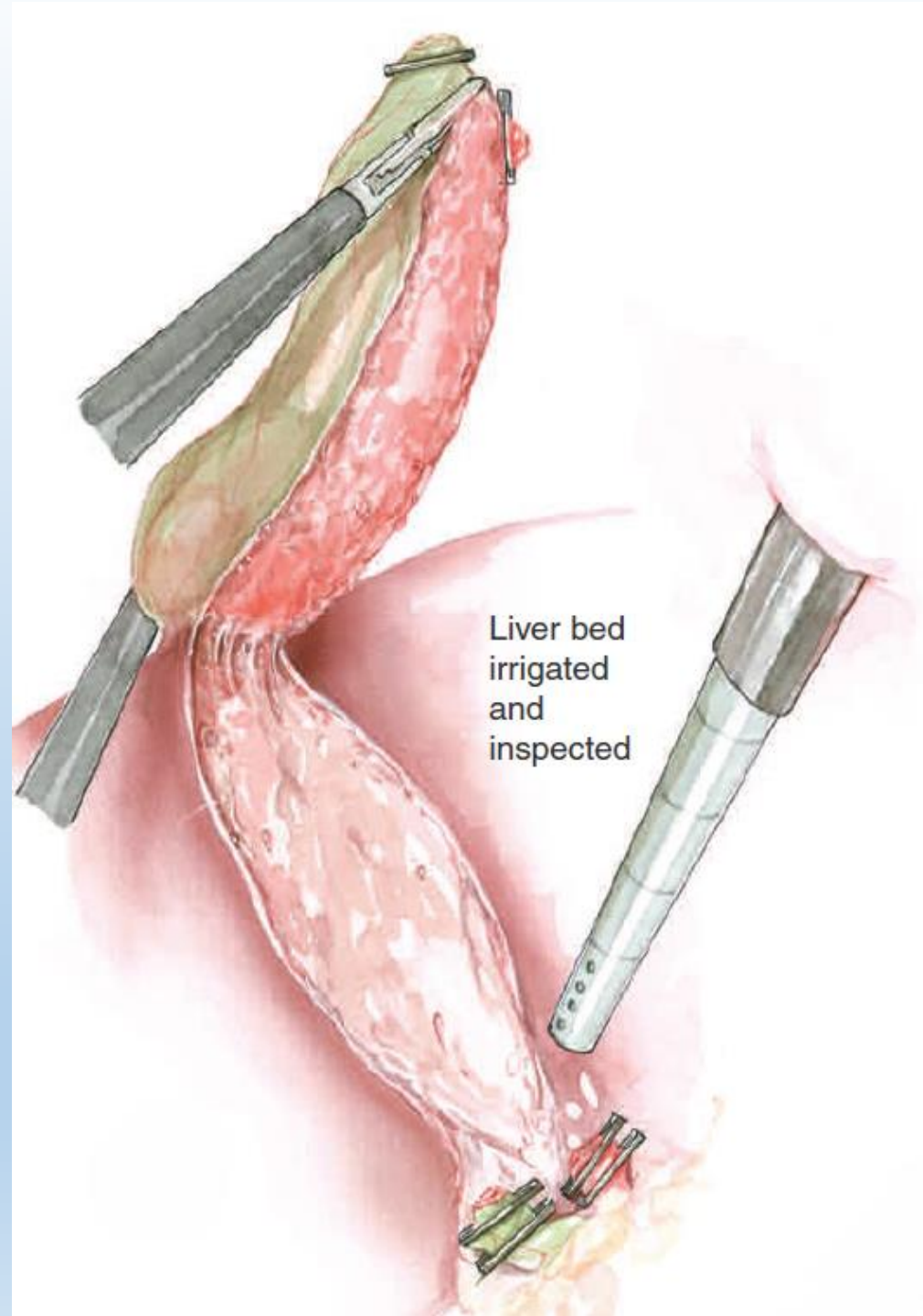


Serosal
edges of gall
bladder
scored with
hook
cautery

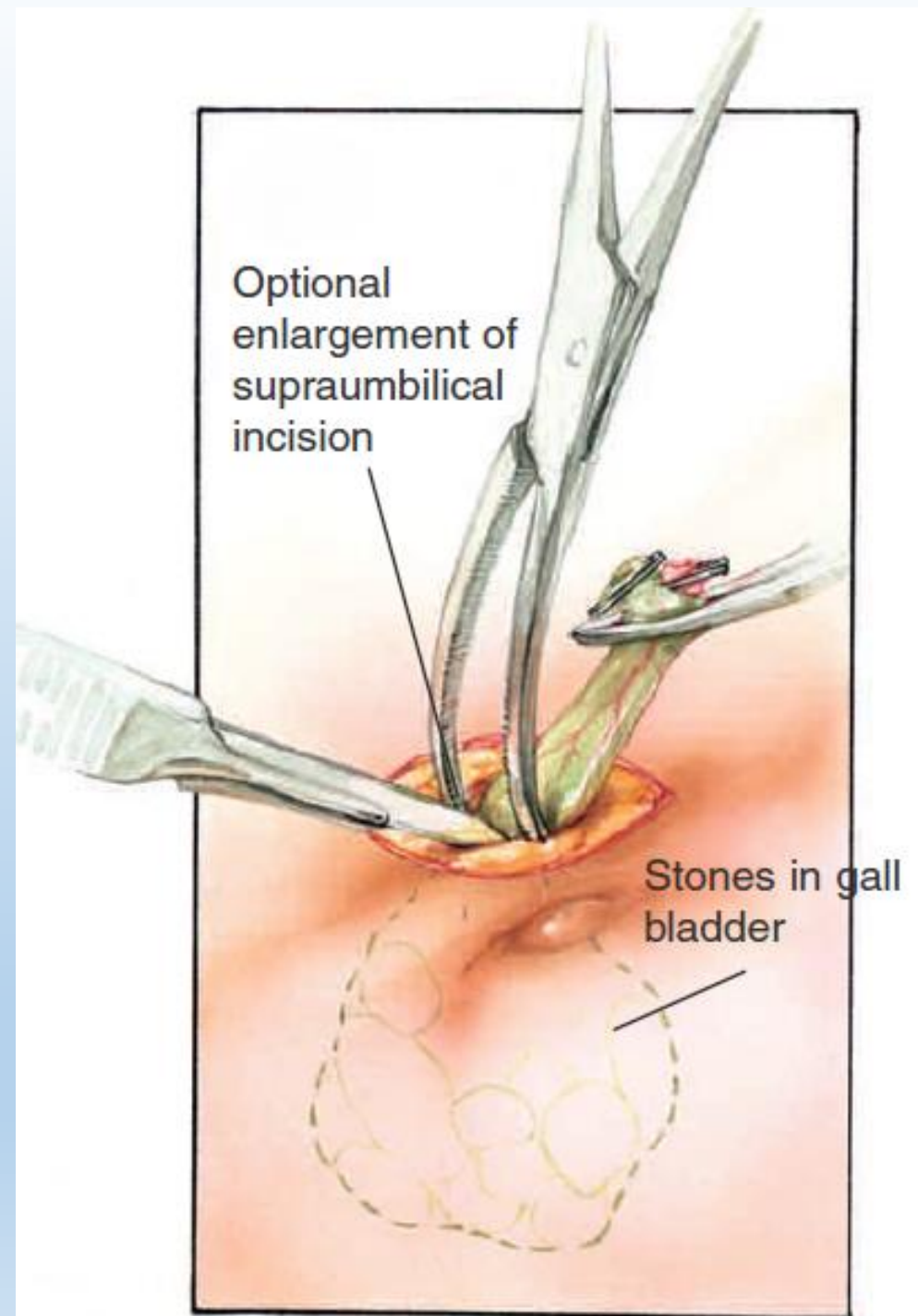
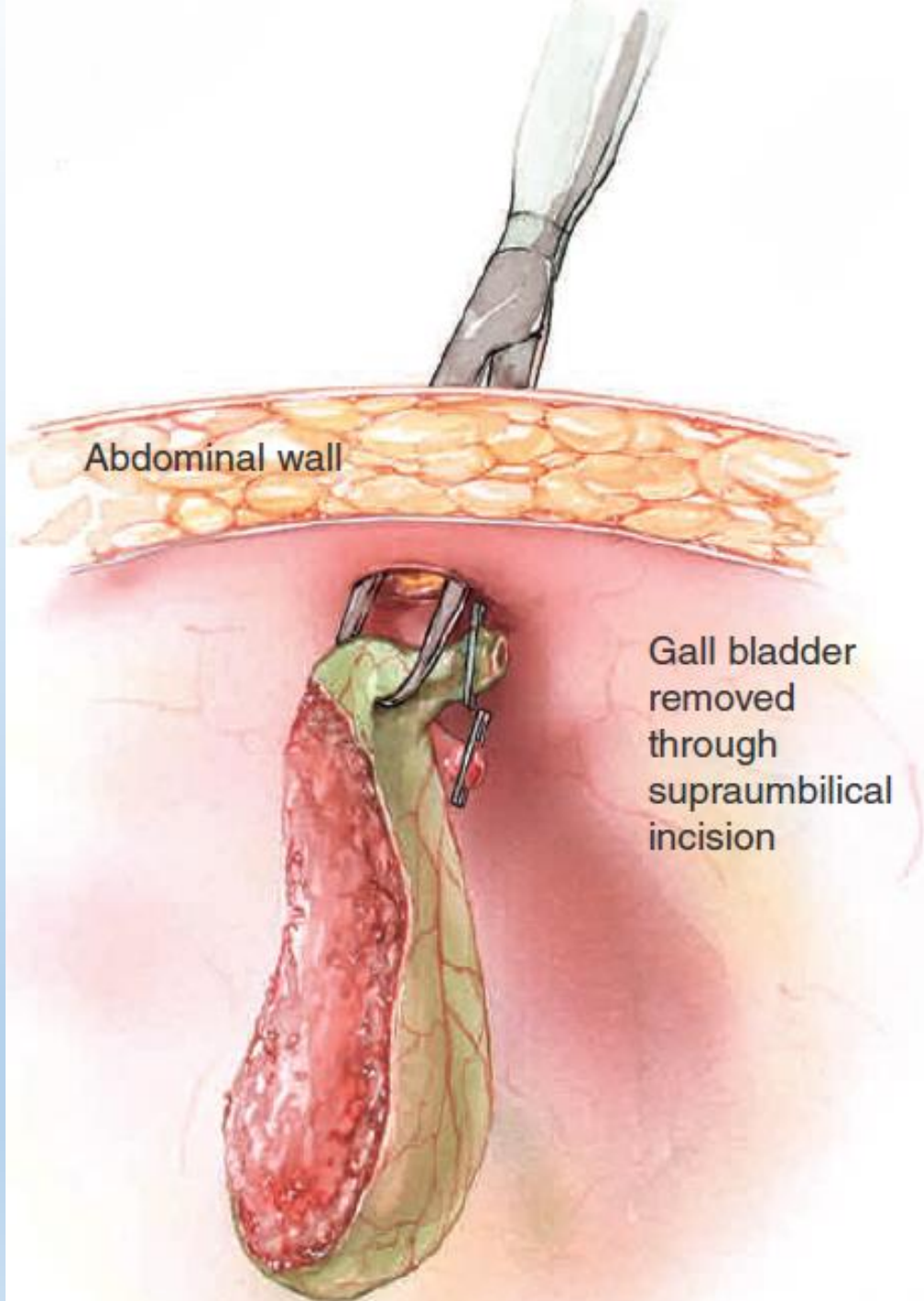


Dissection
continued
toward
fundus

CORINNE
SANDONE

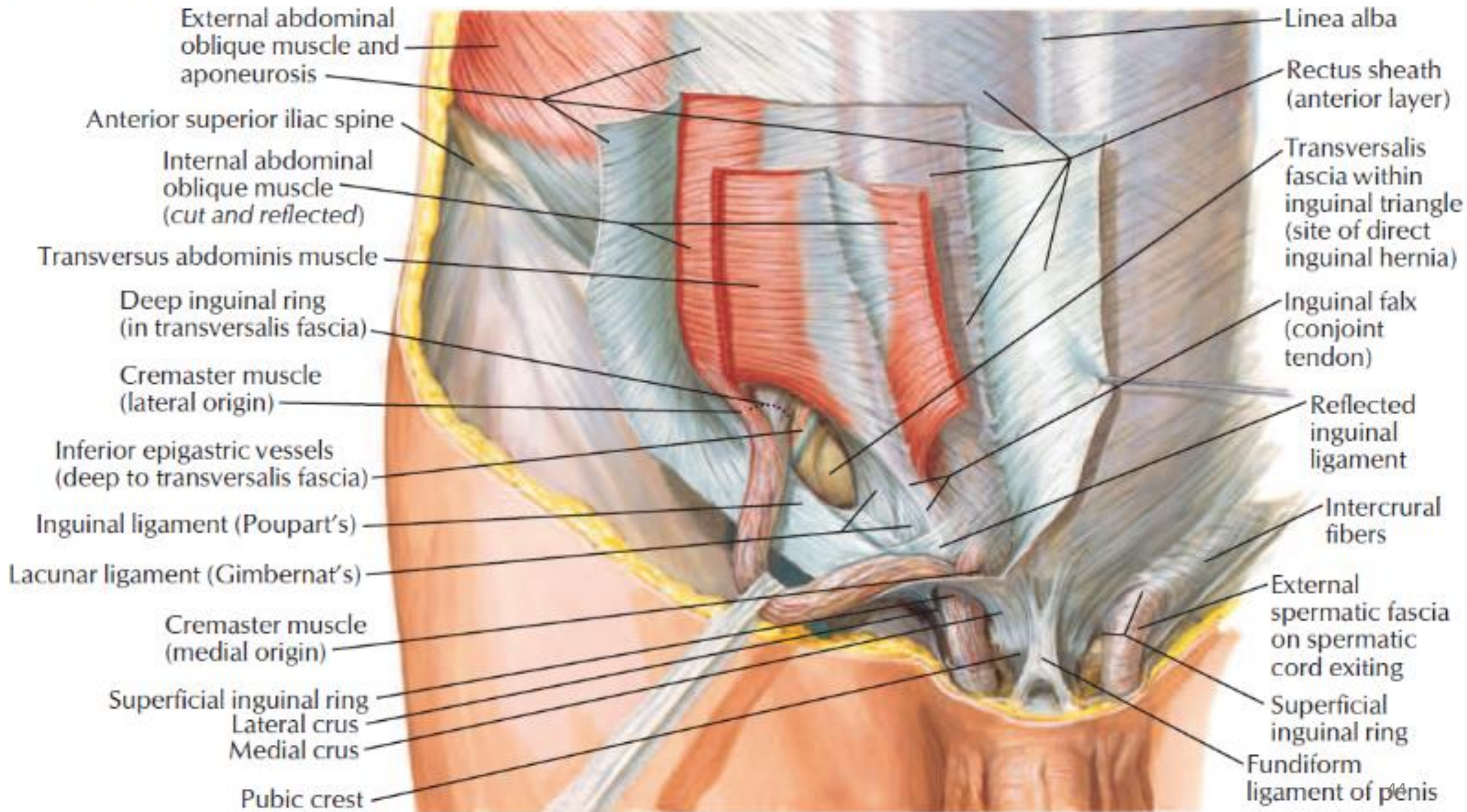


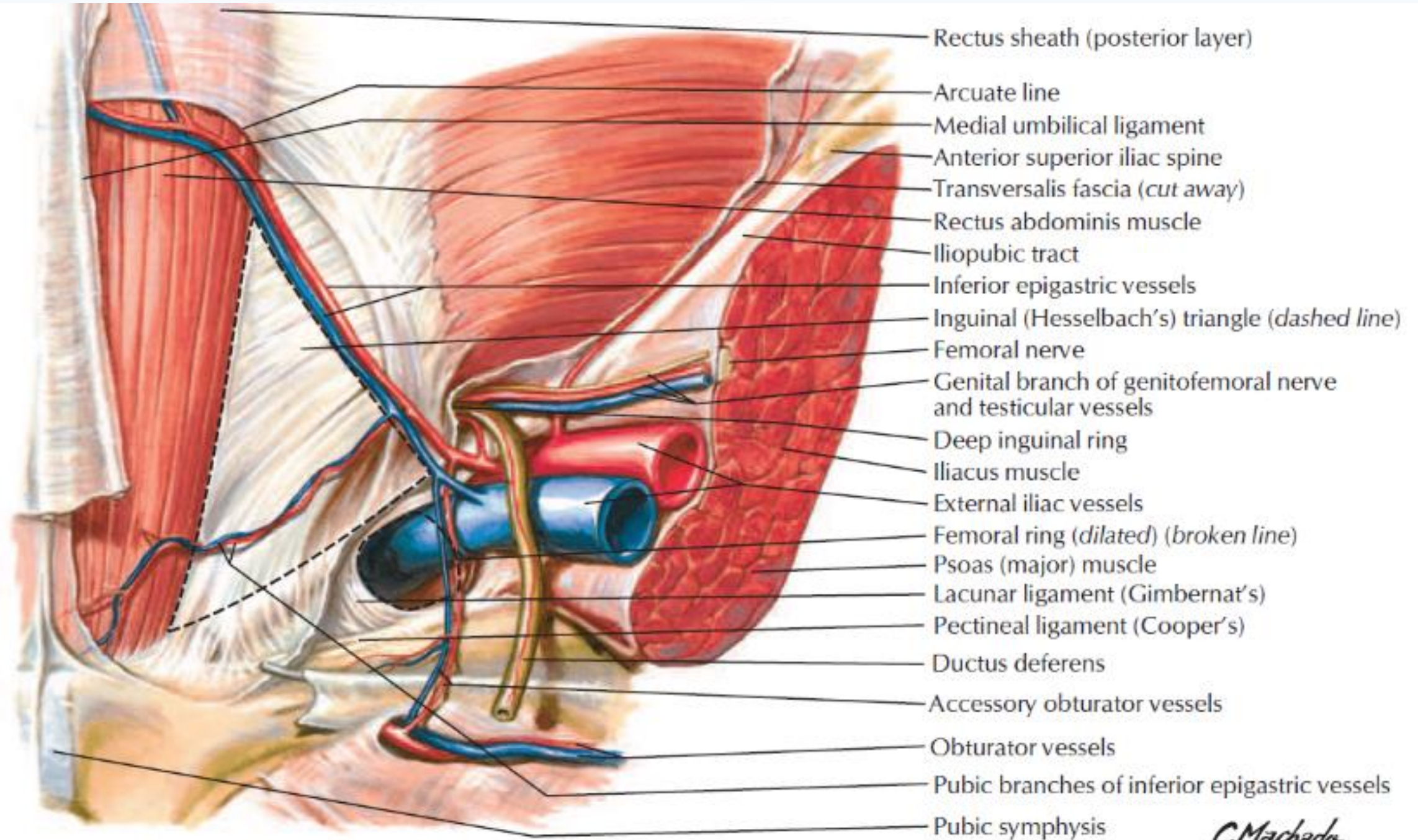
Liver bed
irrigated
and
inspected



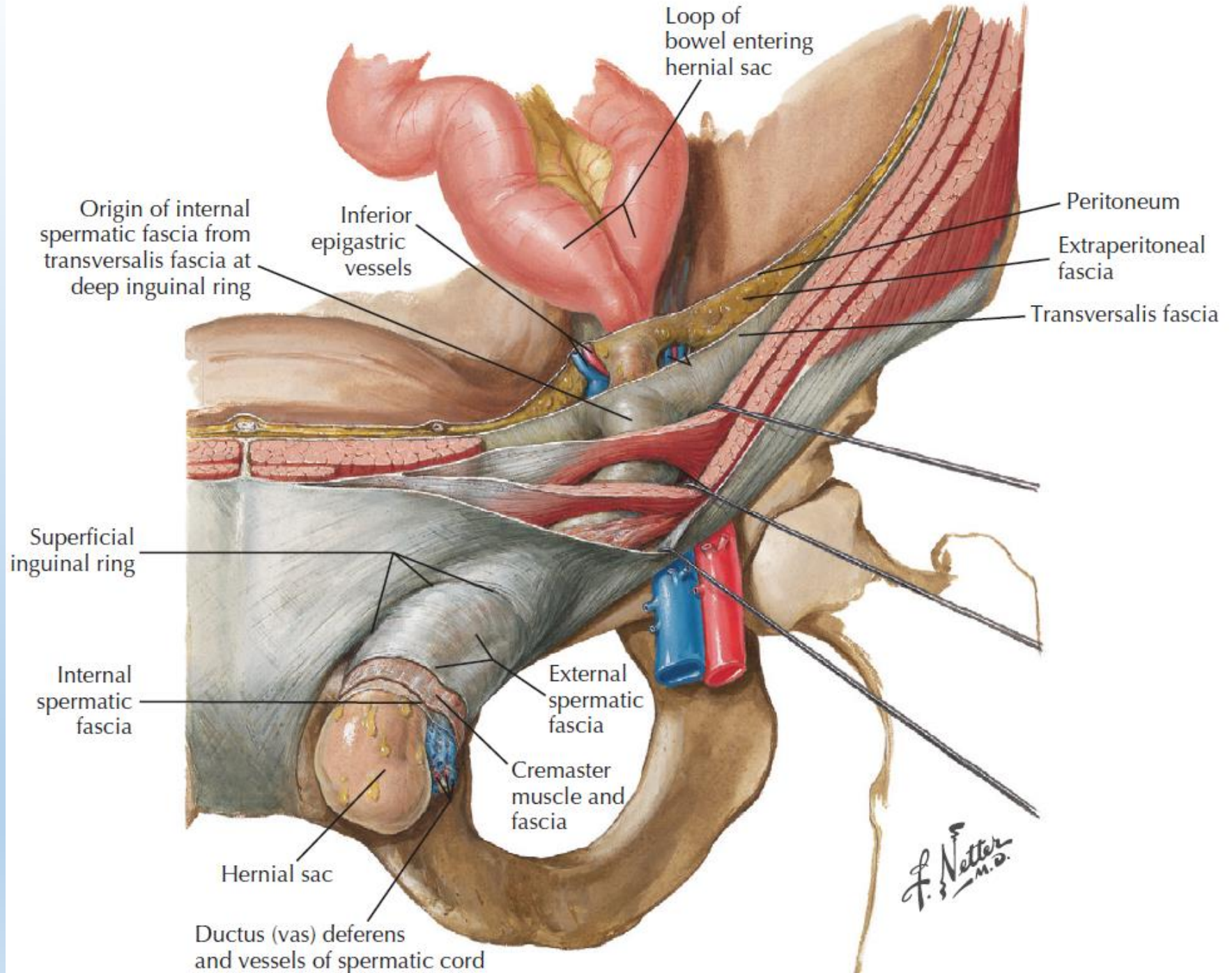
Laparoscopic Inguinal Hernia Repair

Anterior view

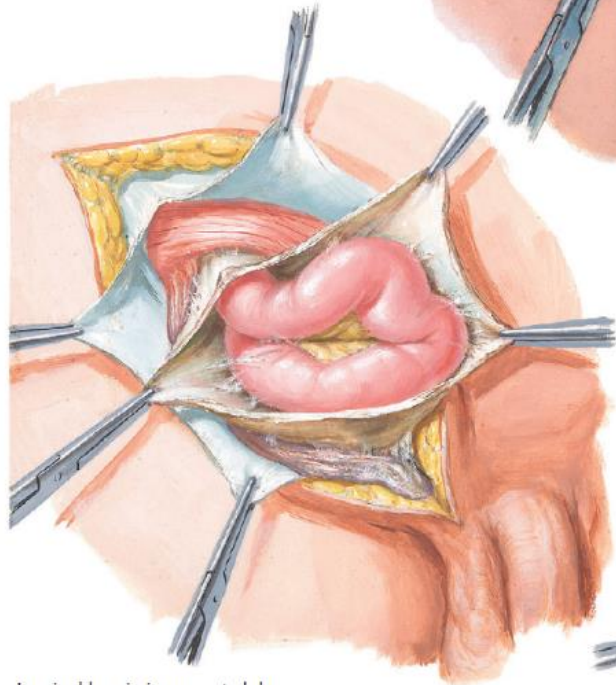
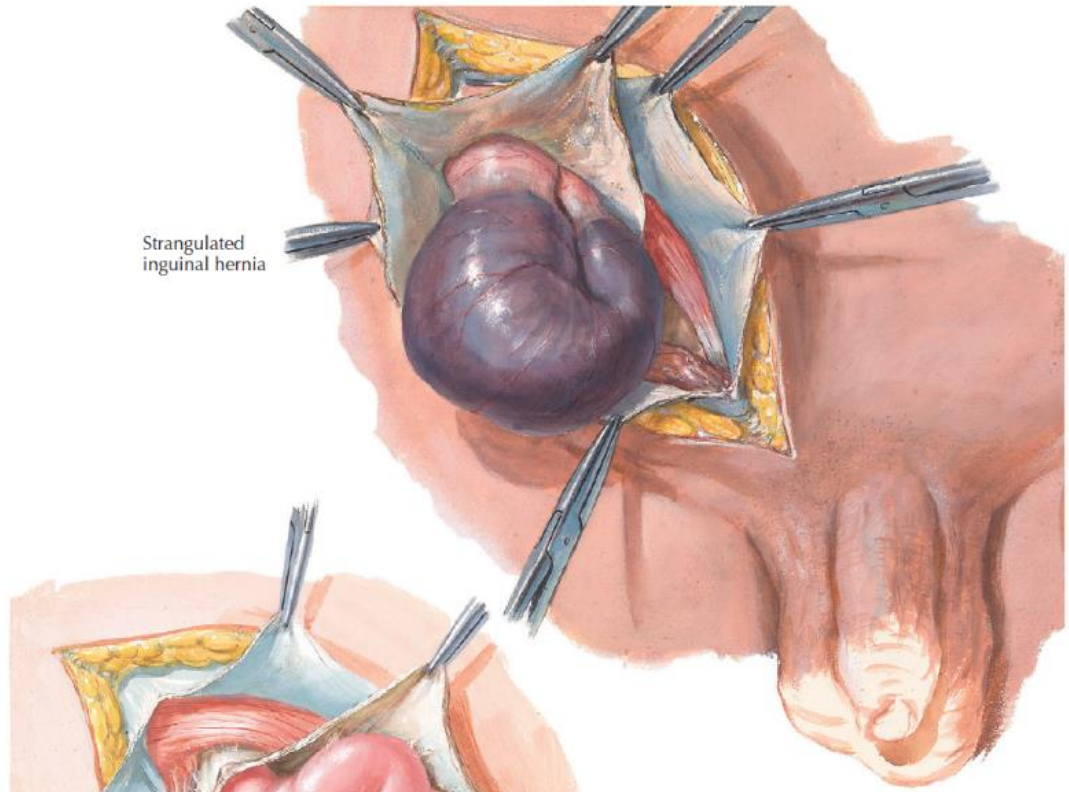




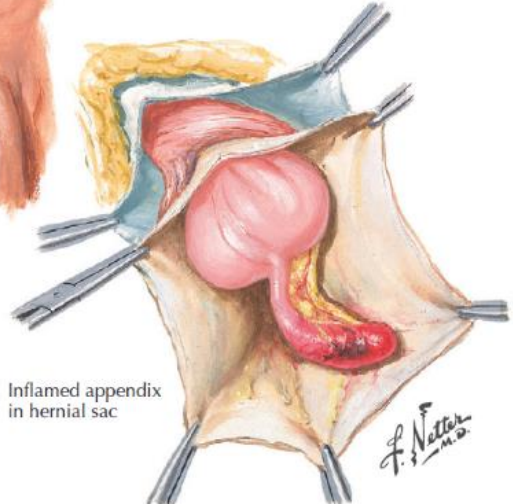
Hesselbach's triangle by Carlos Machado after Frank Netter



Strangulated inguinal hernia



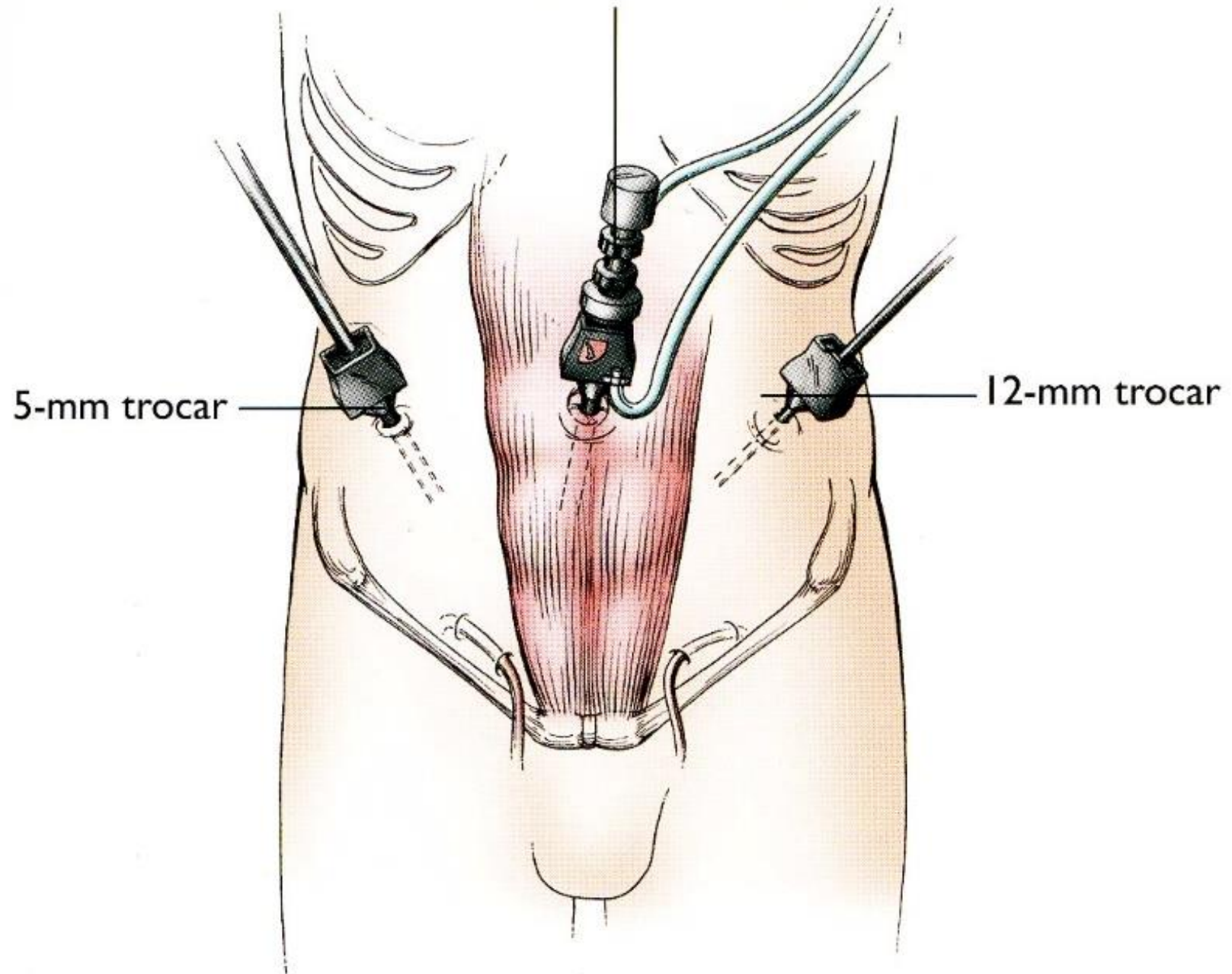
Inguinal hernia incarcerated due to old thickened sac and adhesions

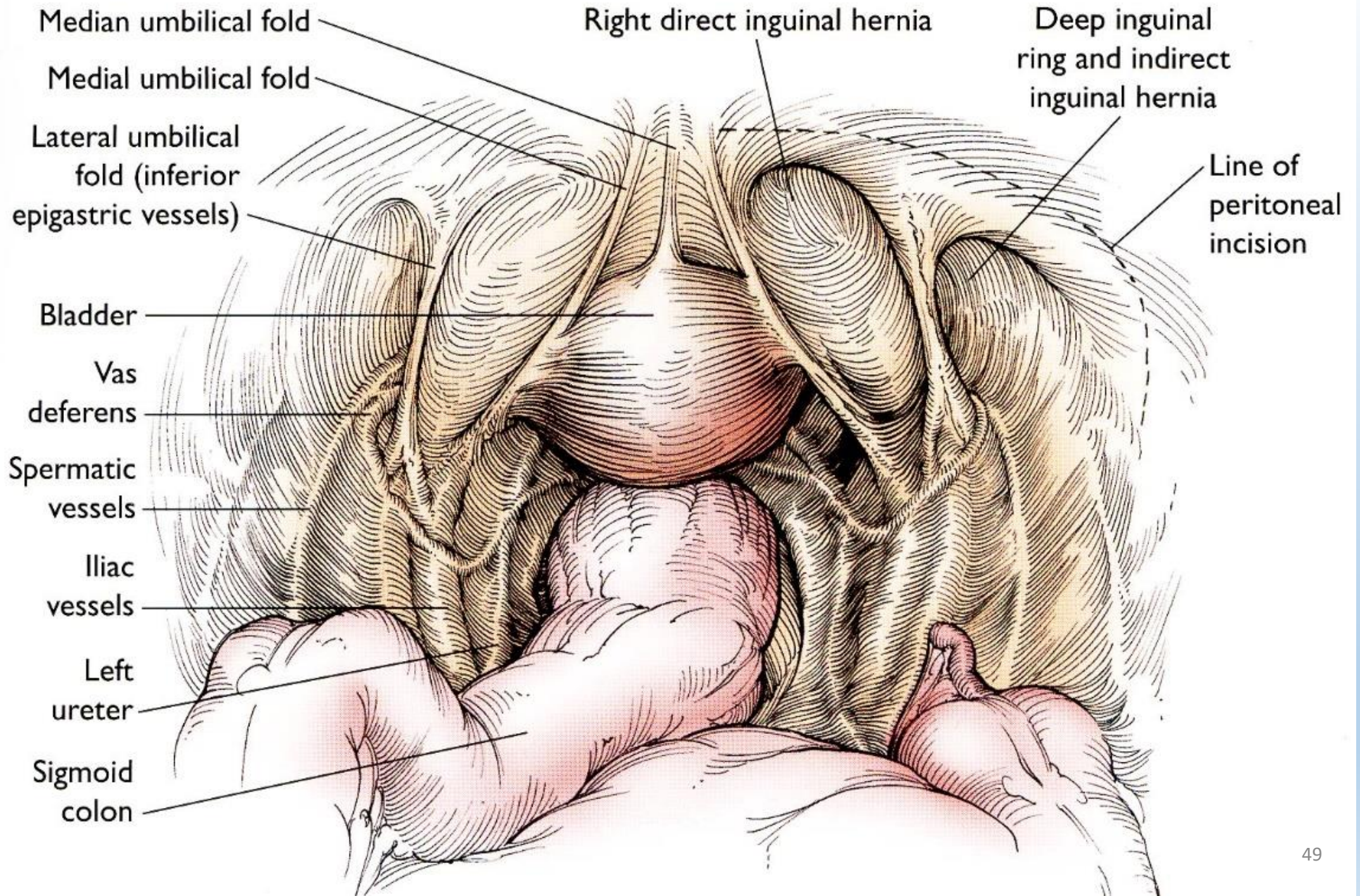


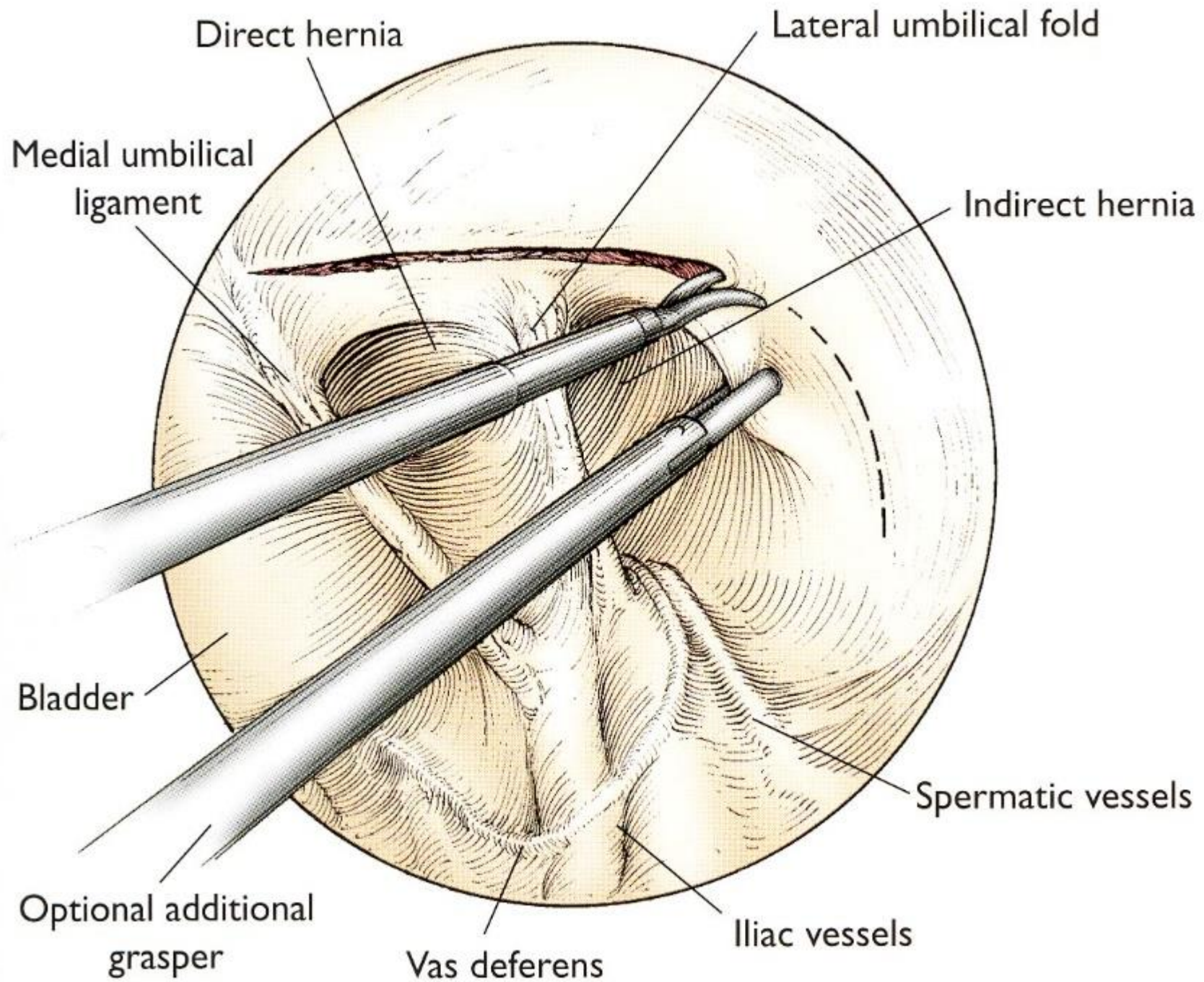
Inflamed appendix in hernial sac

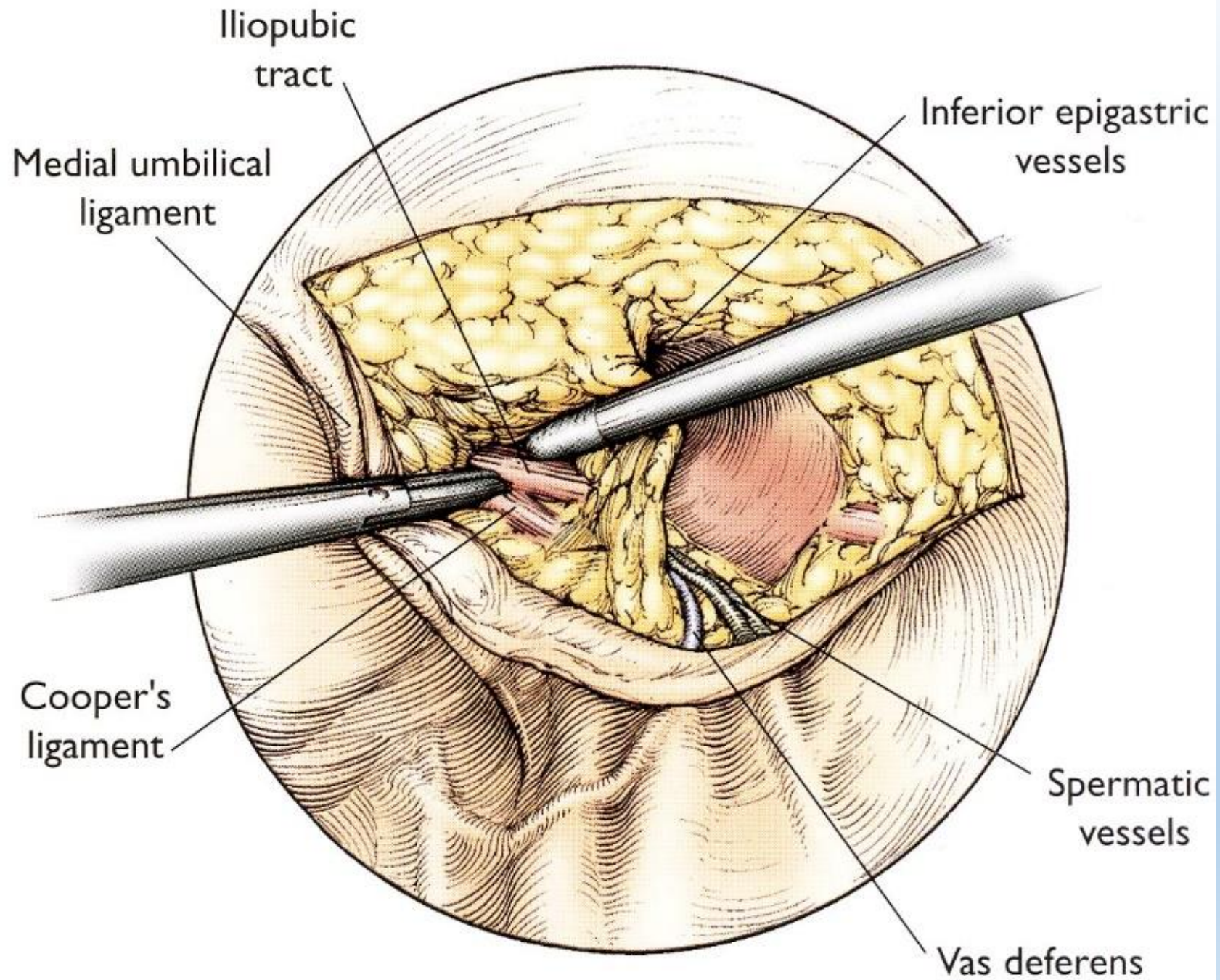
F. Netter M.D.

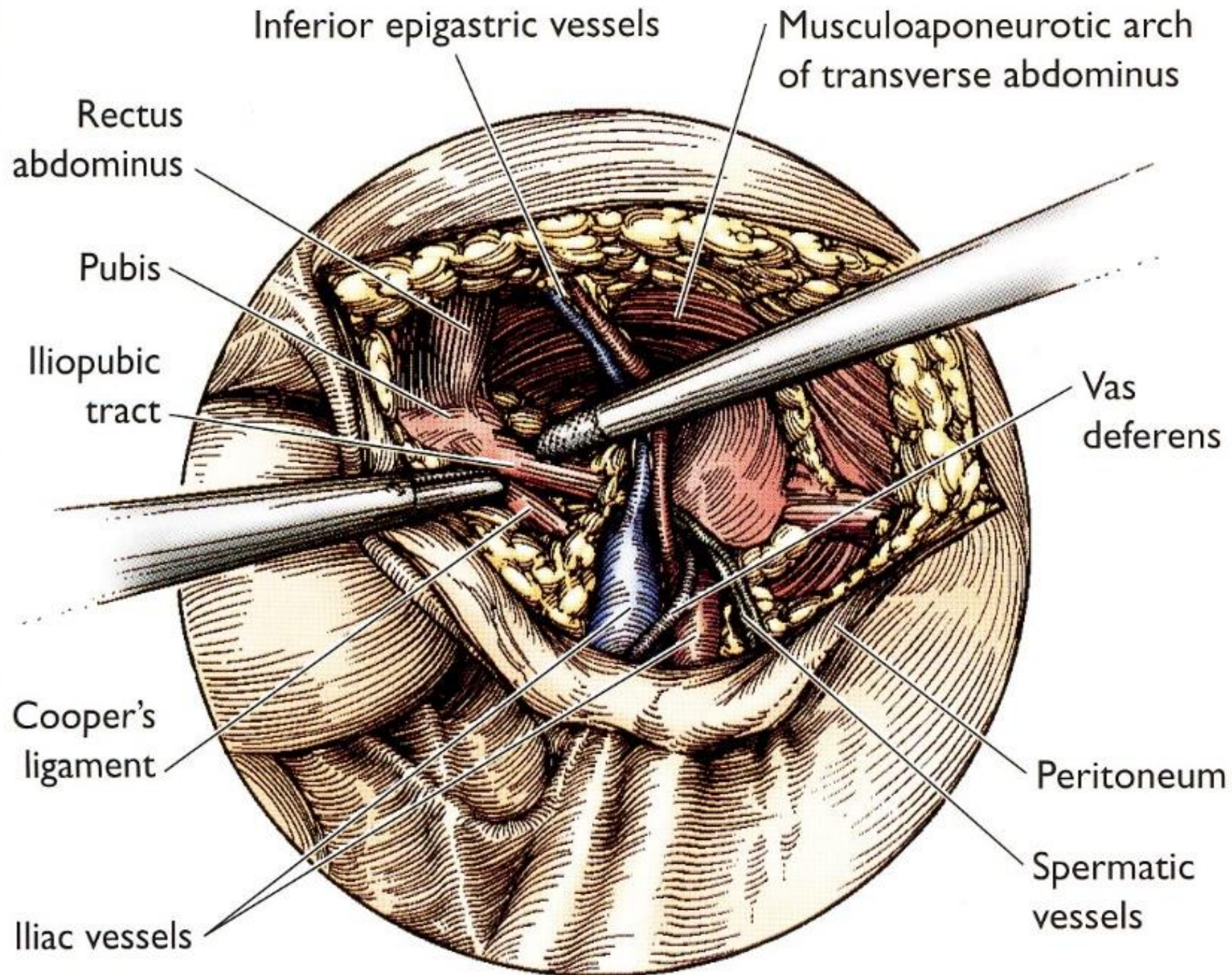
10-mm trocar with camera
and insufflation in umbilicus

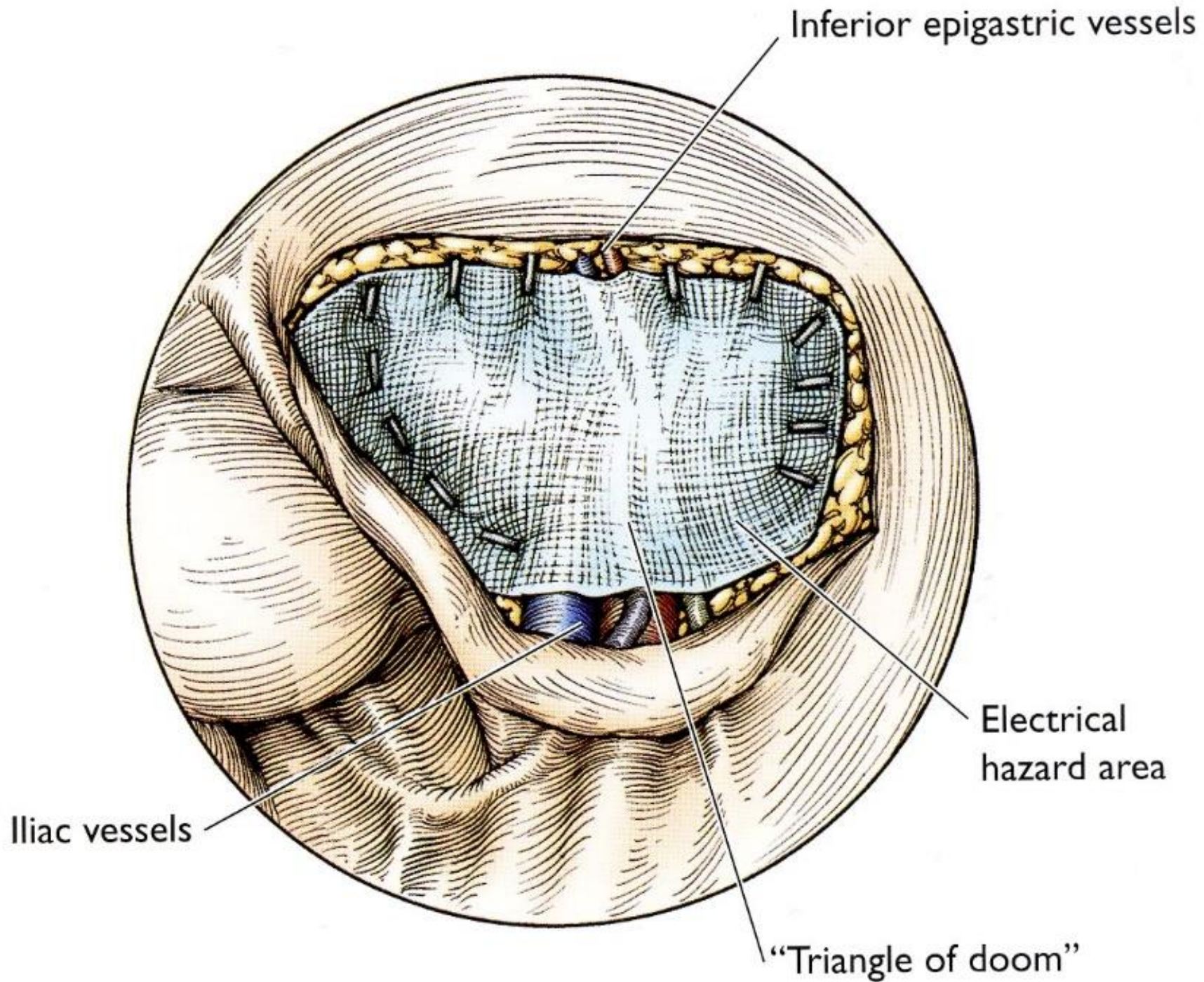




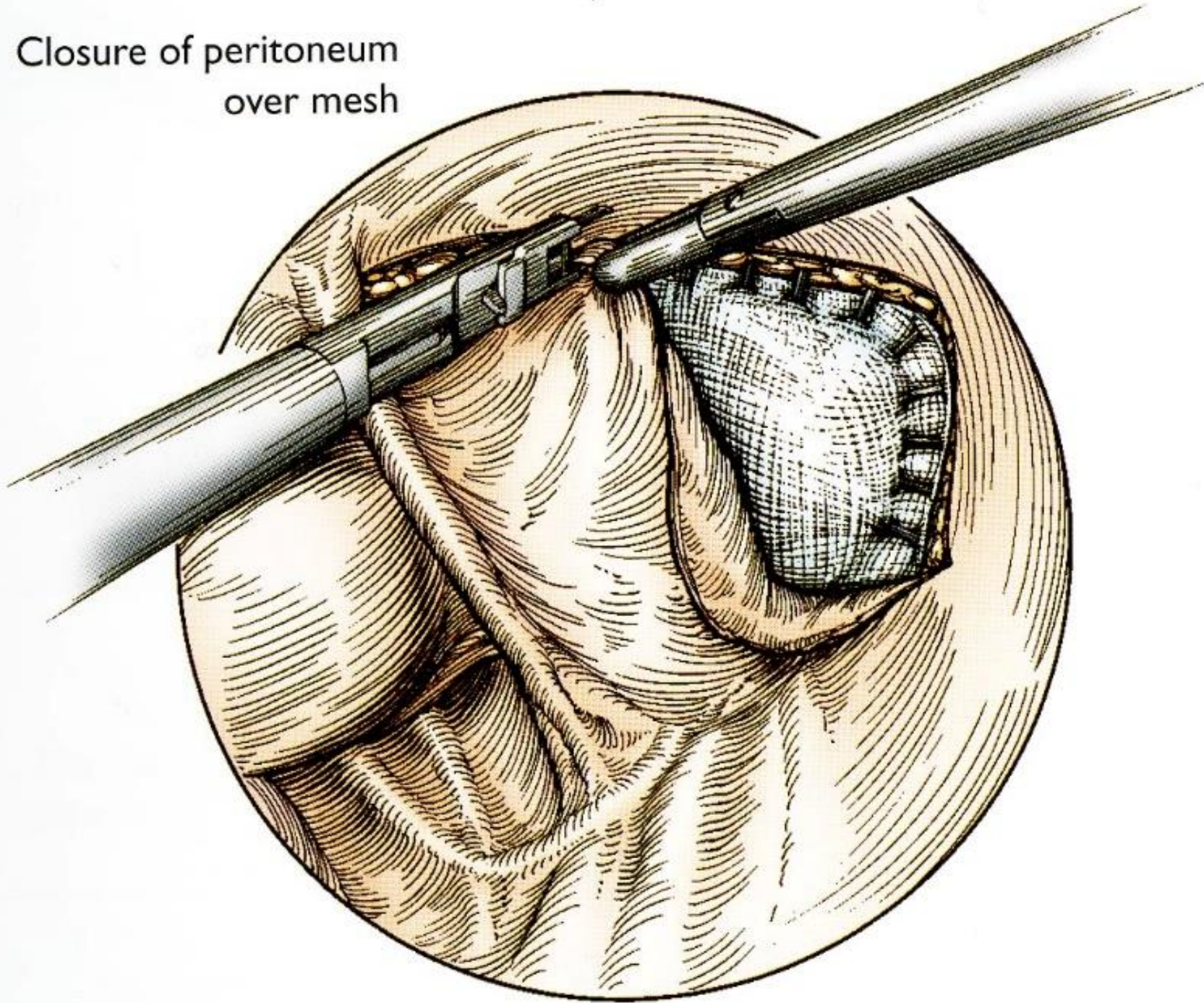








Closure of peritoneum
over mesh



Peritoneum closed
over mesh

